

بِسْمِ اللَّهِ الرَّحْمَنِ الرَّحِيمِ

IN THE NAME OF ALLAH THE MOST
GRACIOUS THE MOST MERCIFUL

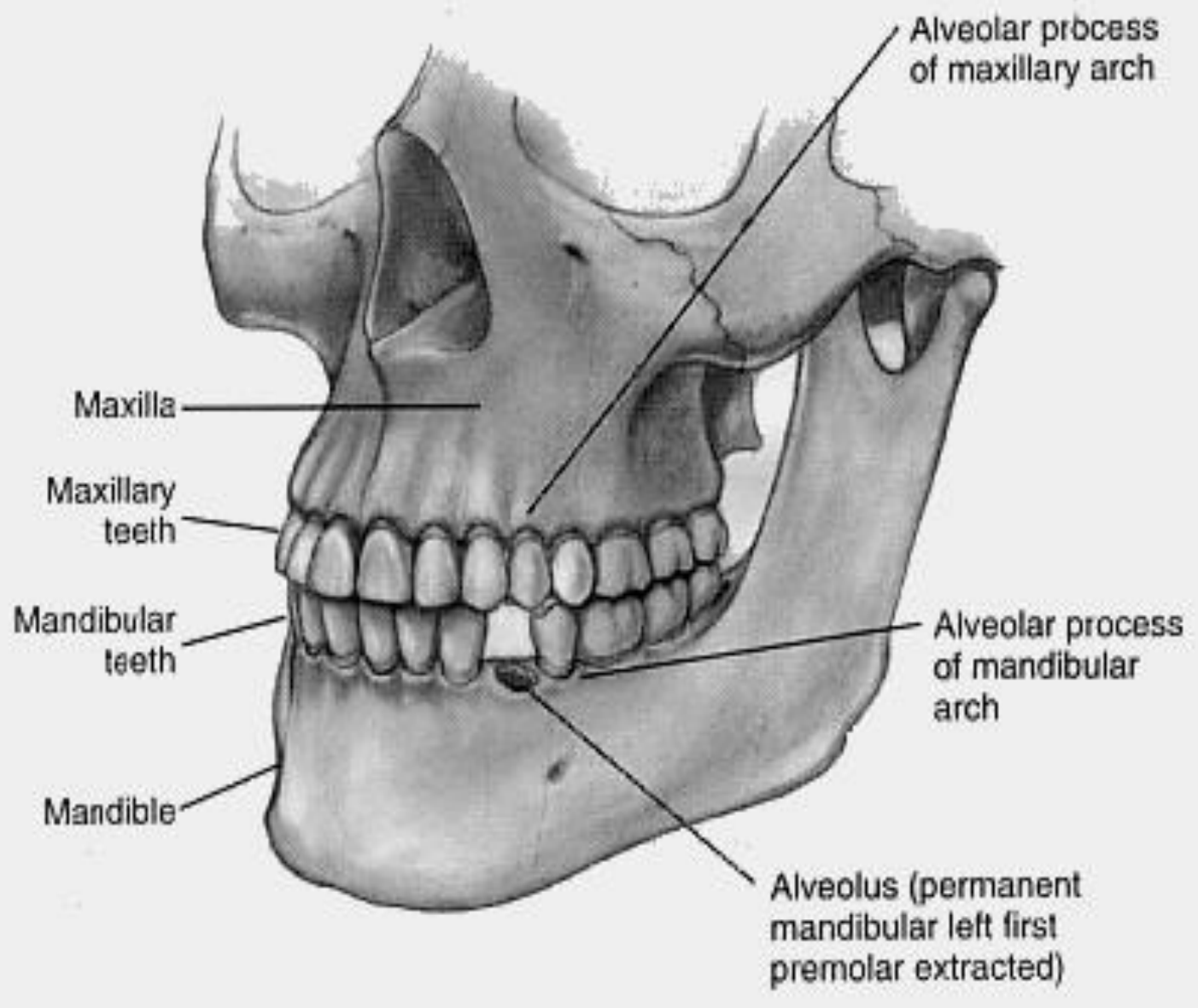
HUMAN DENTITION

DENTAL ANATOMY

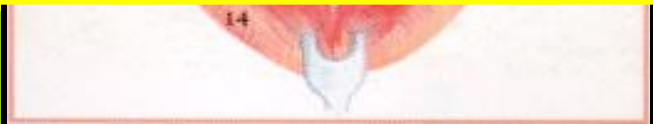Dr Magdy Alabasiry, BDS, MS (Egypt), Ph.D. (Egypt)

INTRODUCTION

D
1.
2.
C
3.
O



CL
CI
MR
R
GIVA)



2- The External Morphology And Internal Composition Of The Individual Teeth.

The Dentitions.

Tooth Anatomy (macroanatomy).

Tooth Anatomy (microanatomy).

Anatomy Of The Pulp Cavity.

Junctions Of Tooth Tissues.

The Periodontium.

Functions Of Teeth.

Tooth Surfaces.

Line And Point Angles.

Division Into Thirds.

Tooth Identification System.

Anatomical Landmarks Of The Crown.

Other Terms.

The Dentitions

Humans have two dentitions

1-The primary dentition: (deciduous)

20 teeth. 10 maxillary and 10 mandibular.

5 teeth are present in each quadrant.

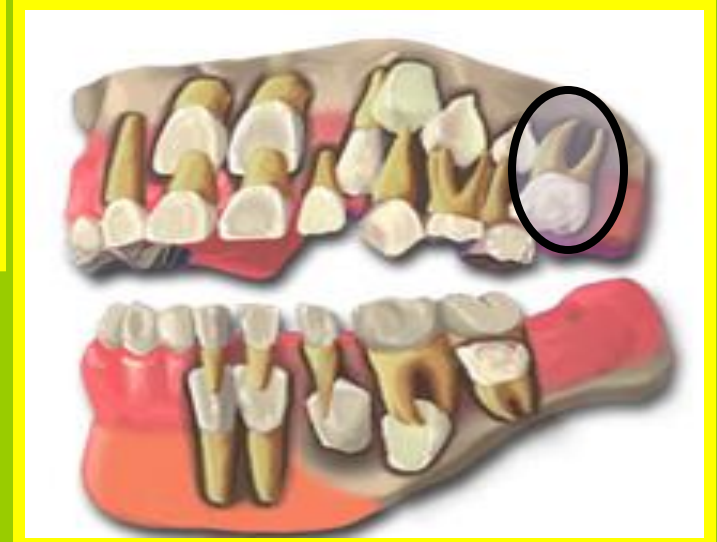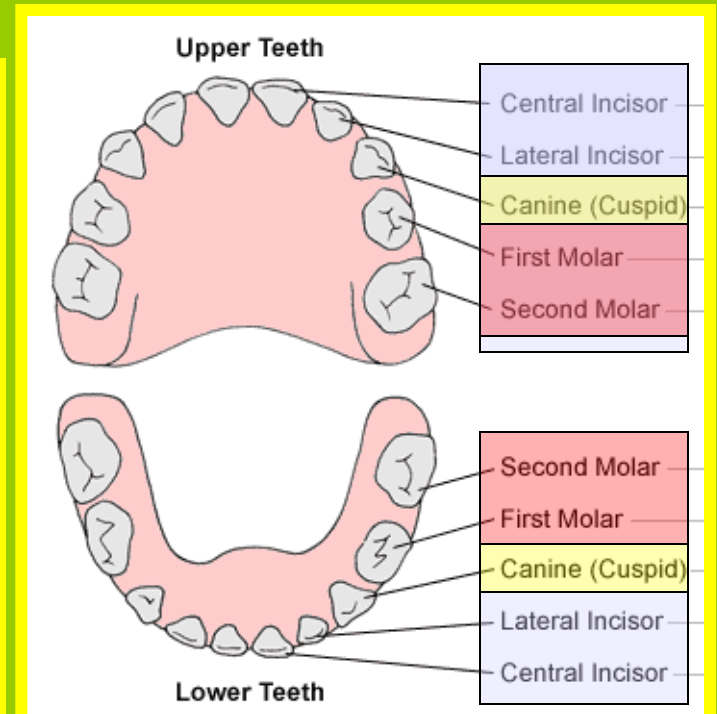
2 incisors.

1 canine.

and 2 molars.

The dental formula is:

$$\begin{array}{ccccccc}
 2 & & 1 & & 2 & & \\
 I & --- & C & ---- & M & ---- & = 10 \\
 2 & & 1 & & 2 & &
 \end{array}$$



The Dentitions

2-The permanent dentition:

(secondary, adult or succedaneous)

32 teeth, 16 maxillary and 16 mandibular.

8 teeth in each quadrant are Present.

2 incisors.

1 canine.

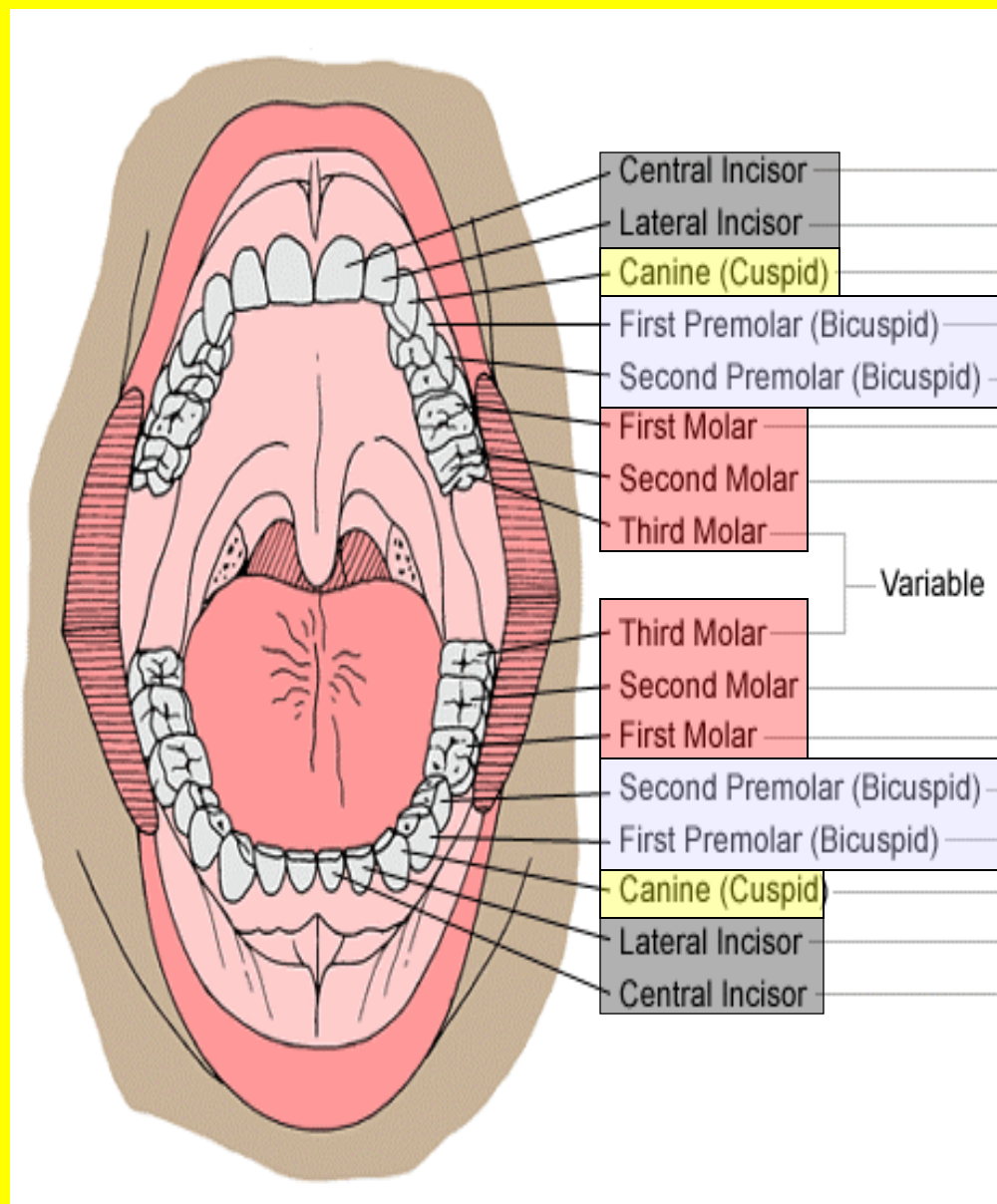
2 premolars.

and 3 molars.

The dental formula is :

$$\begin{array}{ccccccc}
 2 & 1 & 2 & 3 & & & \\
 I & - & C & - & PM & - & M & - & = & 16 \\
 2 & 1 & 2 & 3 & & & & & &
 \end{array}$$

The *permanent molars* are not preceded with deciduous teeth so they may be termed as *non-succedaneous teeth*.



The Dentitions

SUMMARY

Humans have two dentitions

1-The primary dentition: (deciduous)

20 teeth. 10 maxillary and 10 mandibular.

5 teeth are present in each quadrant.

2 incisors, 1 canine and 2 molars.

The dental formula is:

$$\begin{array}{cccc} 2 & 1 & 2 & \\ I \text{ ---} & C \text{ ----} & M \text{ ----} & = 10 \\ 2 & 1 & 2 & \end{array}$$

2-The permanent dentition: (secondary, adult or succedaneous)

32 teeth, 16 maxillary and 16 mandibular,

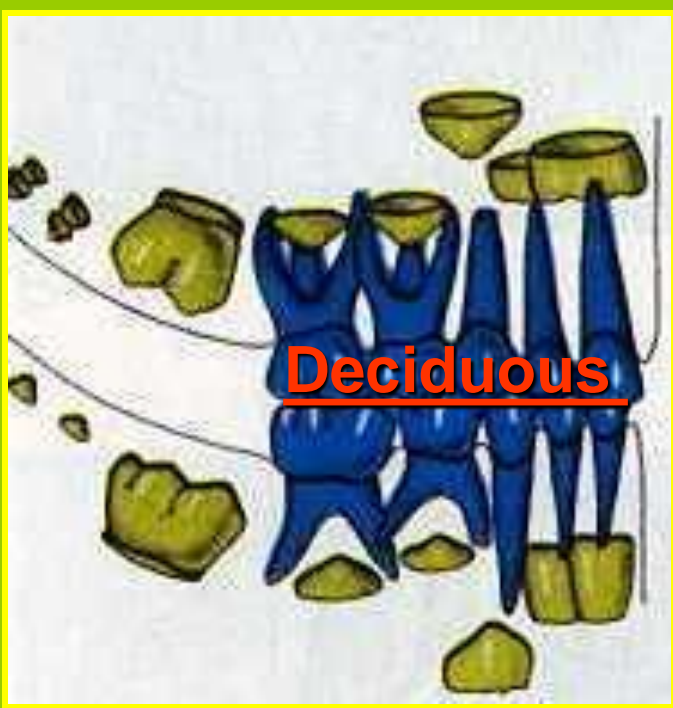8 teeth in each quadrant are present,

2 incisors, 1 canine, 2 premolars and 3 molars.

The dental formula is :

$$\begin{array}{cccc} 2 & 1 & 2 & 3 \\ I \text{ ----} & C \text{ ----} & PM \text{ ---} & M \text{ ----} = 16 \\ 2 & 1 & 2 & 3 \end{array}$$

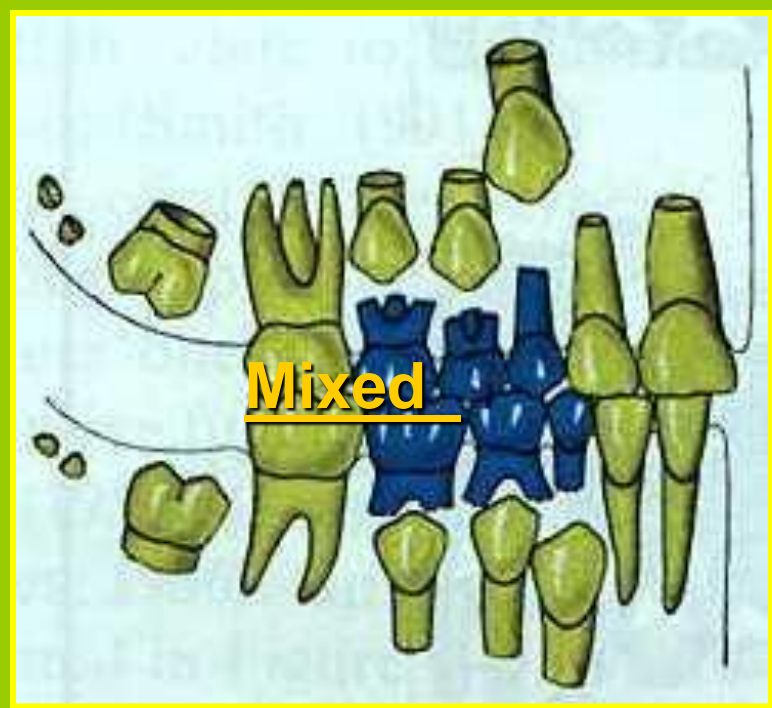
The **permanent molars** are not preceded with deciduous teeth so they may be termed as **non-succedaneous teeth**.



Deciduous

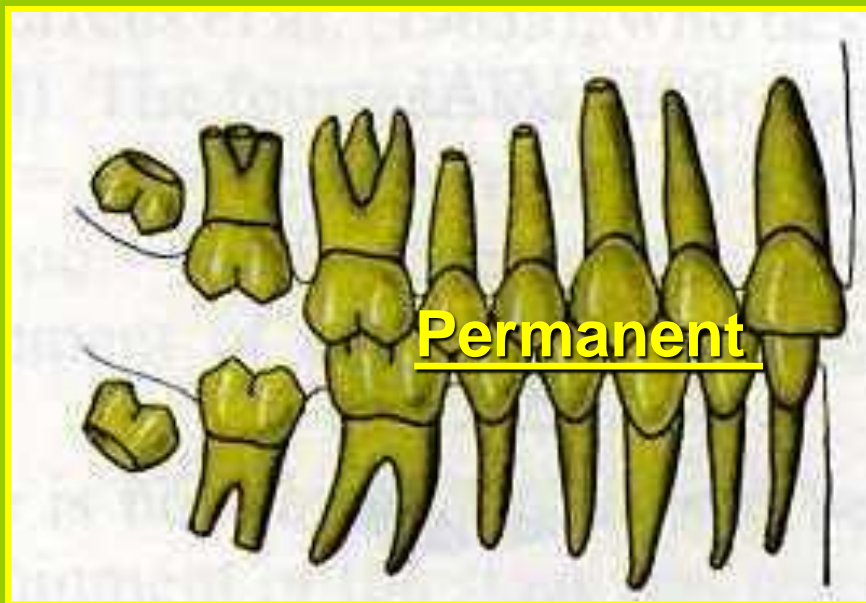Primary dentition
6 m - 6 y

Shedding: It is the physiological loss of the deciduous teeth and their subsequent replacement by permanent teeth.



Mixed

Mixed dentition
6 y - 12 y



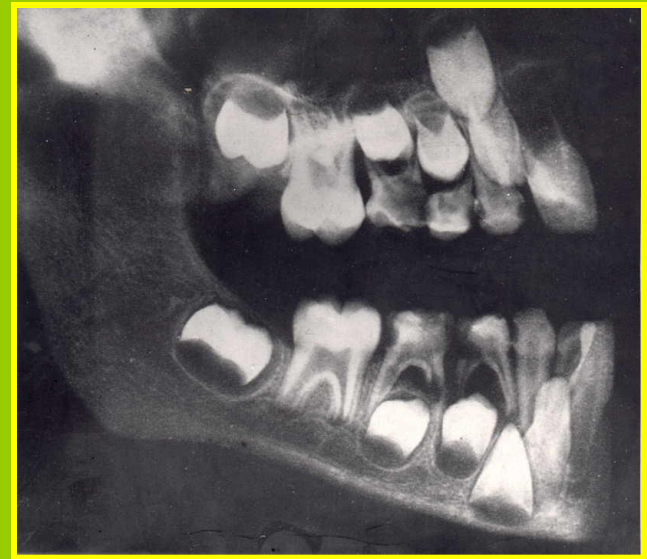
Permanent

Permanent dentition 12 y and up

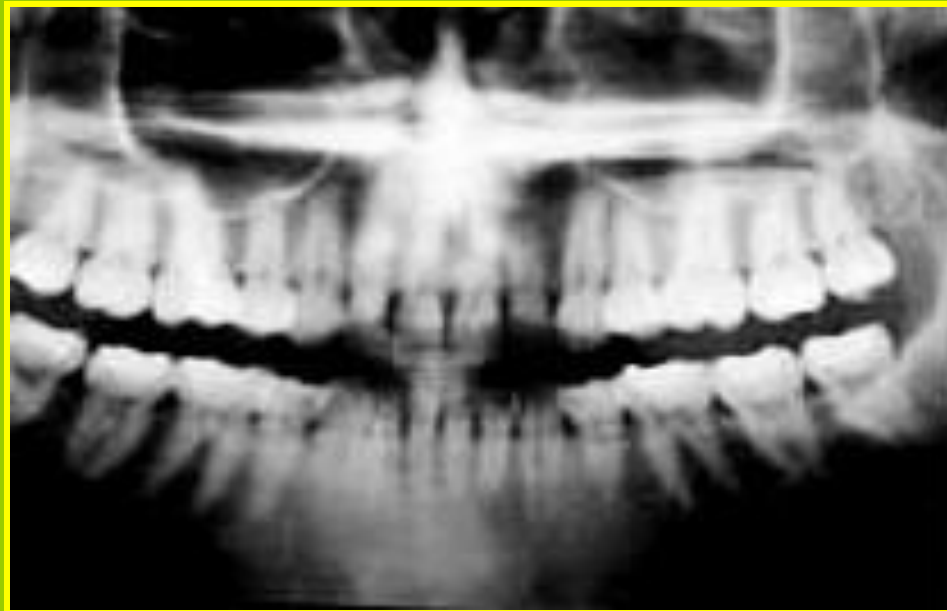


1- Primary dentition
6 m - 6 y

X – Ray Showing



2- Mixed dentition
6 y - 12 y



3- Permanent dentition 12 y and up

Tooth Anatomy

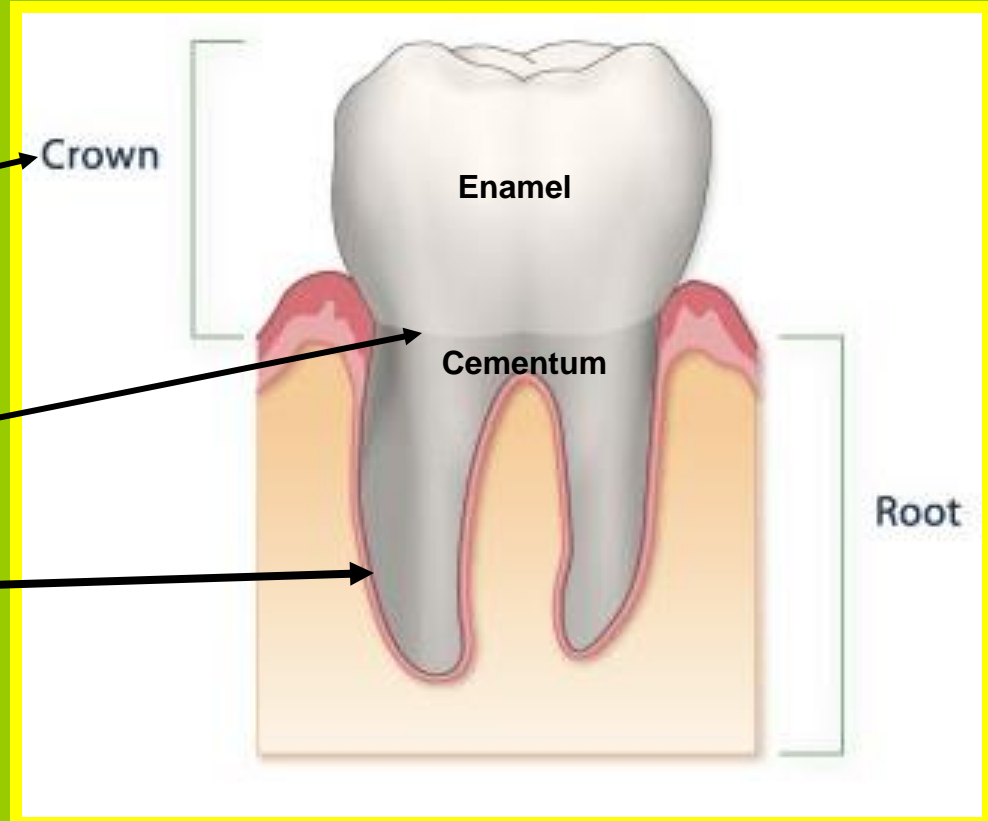
1- Macro-anatomy of the tooth

Each tooth has three anatomical parts:

I. Crown

II. The Neck: cervical line or cemento-enamel junction (CEJ).

II. Root (s)



Anatomical And Clinical Crown And Root

Clinical Crown

Anatomical Crown

Portion of anatomical crown that is visible in the oral cavity

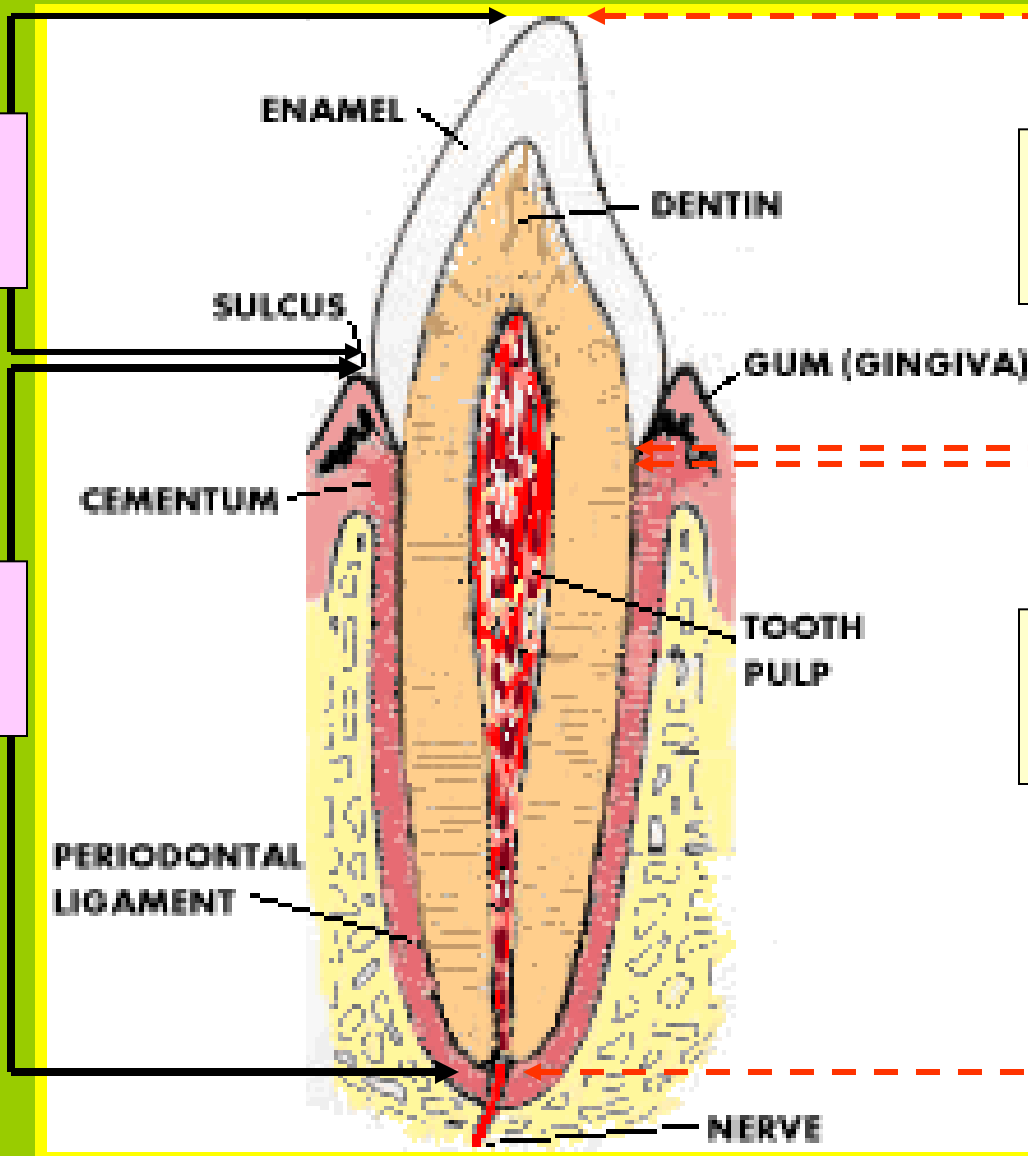
It is the portion of the tooth that covered by enamel

Clinical Root

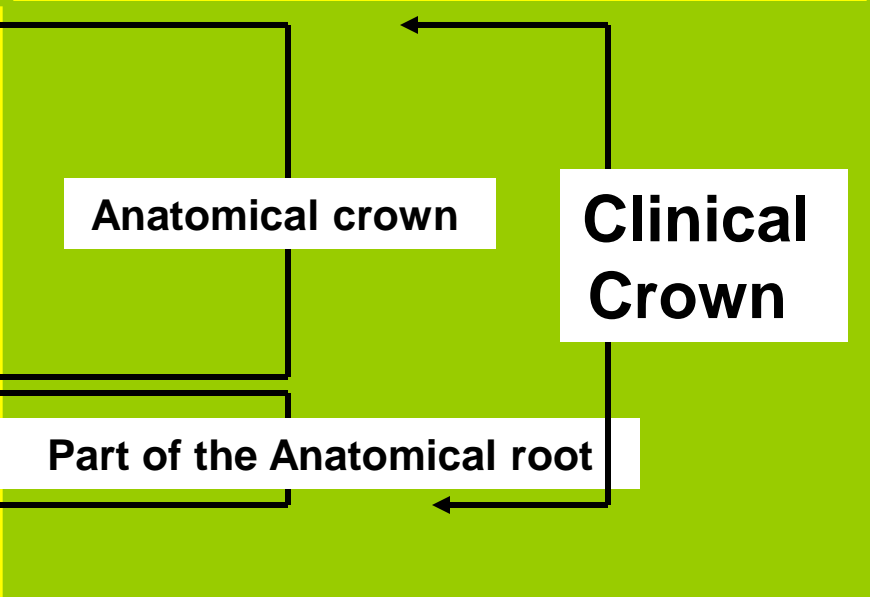
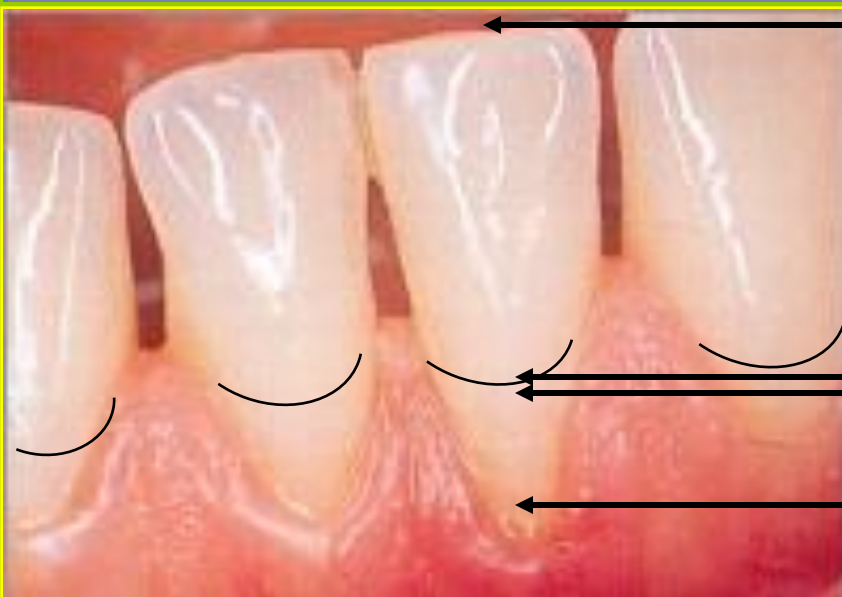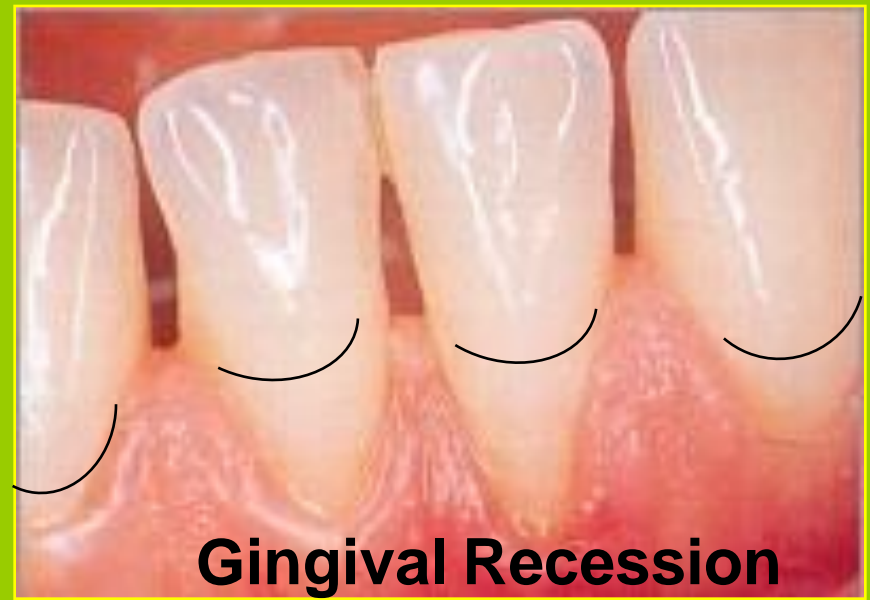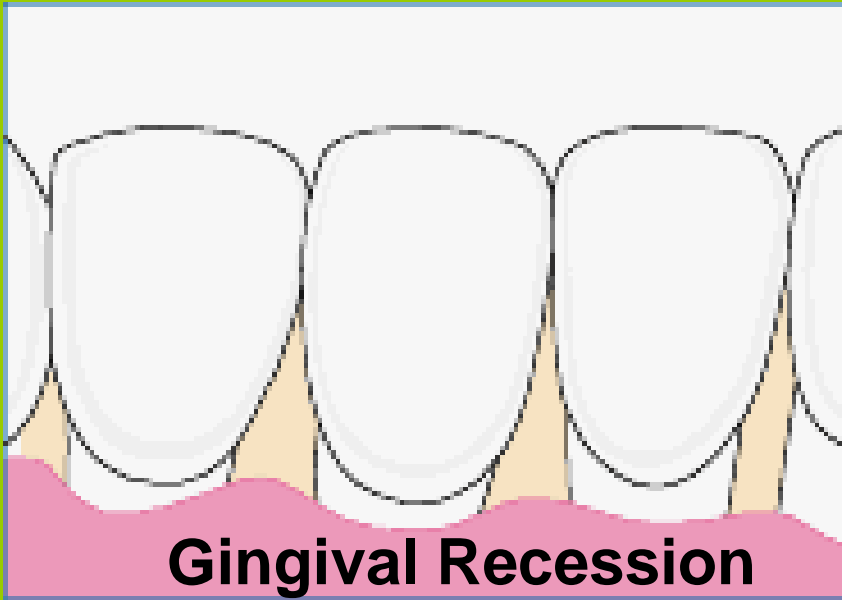Anatomical Root

Part of a tooth not exposed to the oral cavity

It is the portion of the tooth that covered by cementum



Anatomical And Clinical Crown And Root

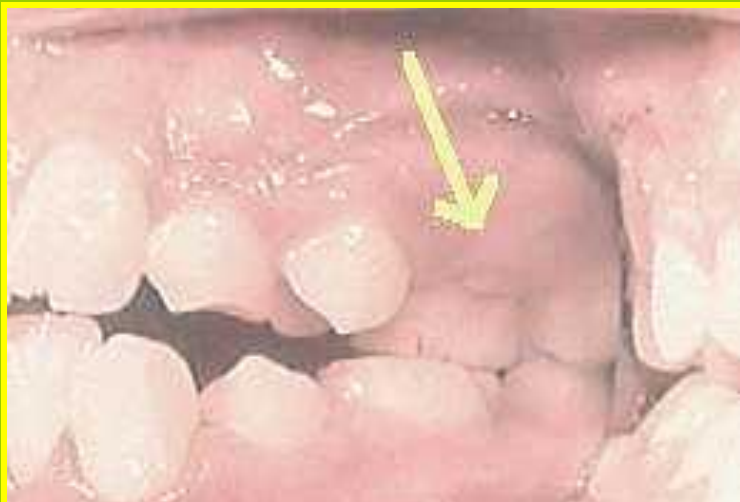

Anatomical crown

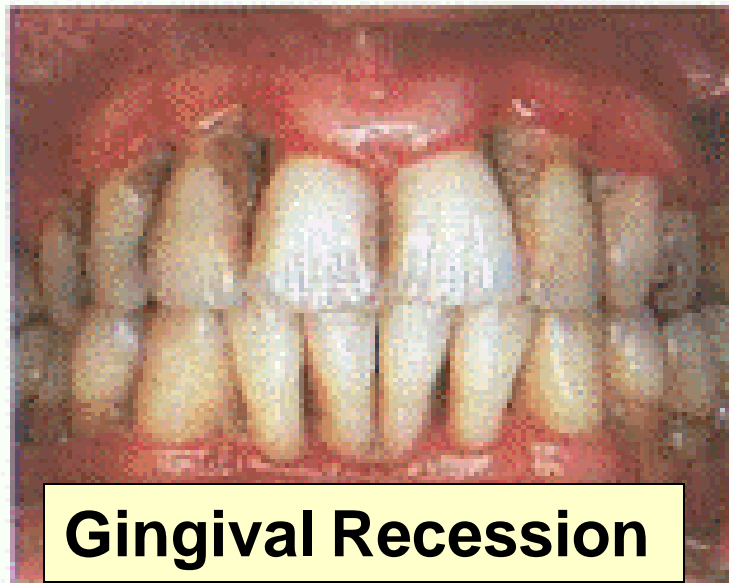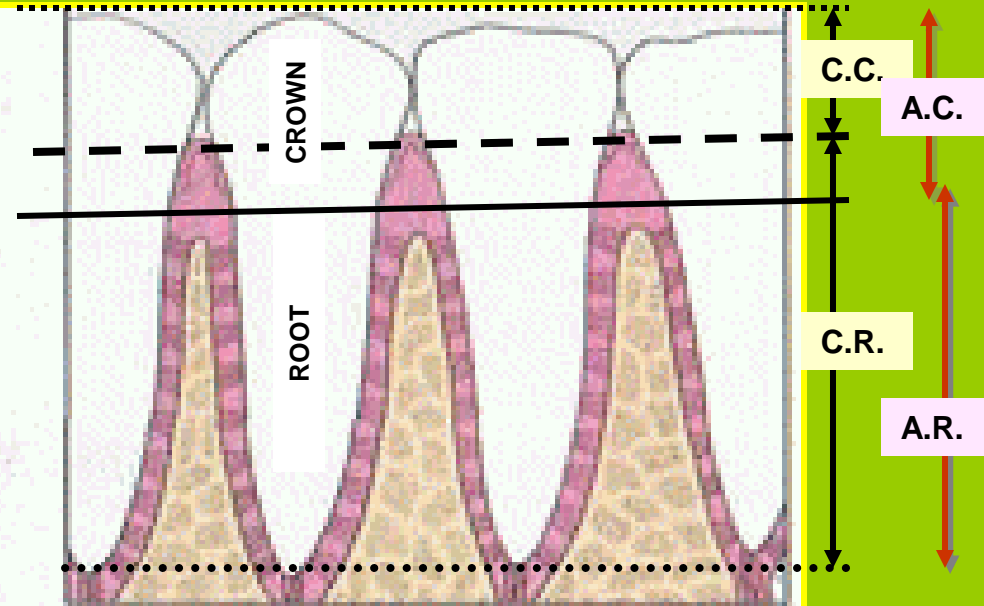
**Clinical
Crown**

Part of the Anatomical root

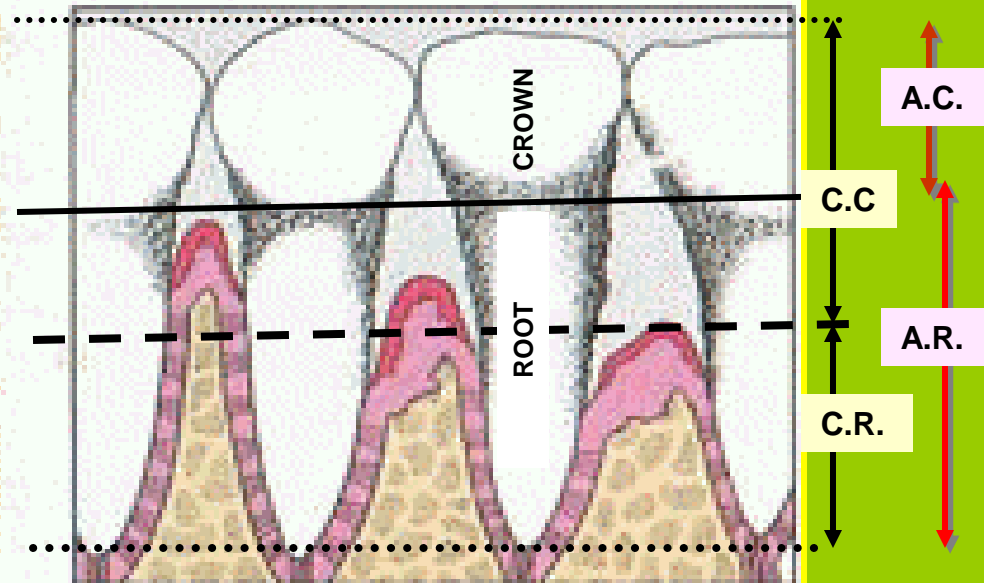
Anatomical And Clinical Crown And Root



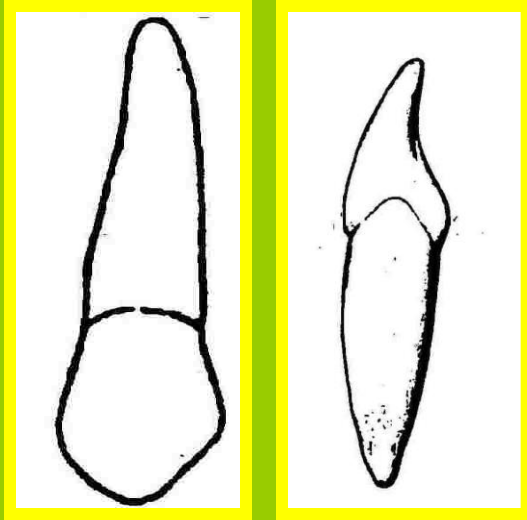
Newly Erupted Teeth



Gingival Recession

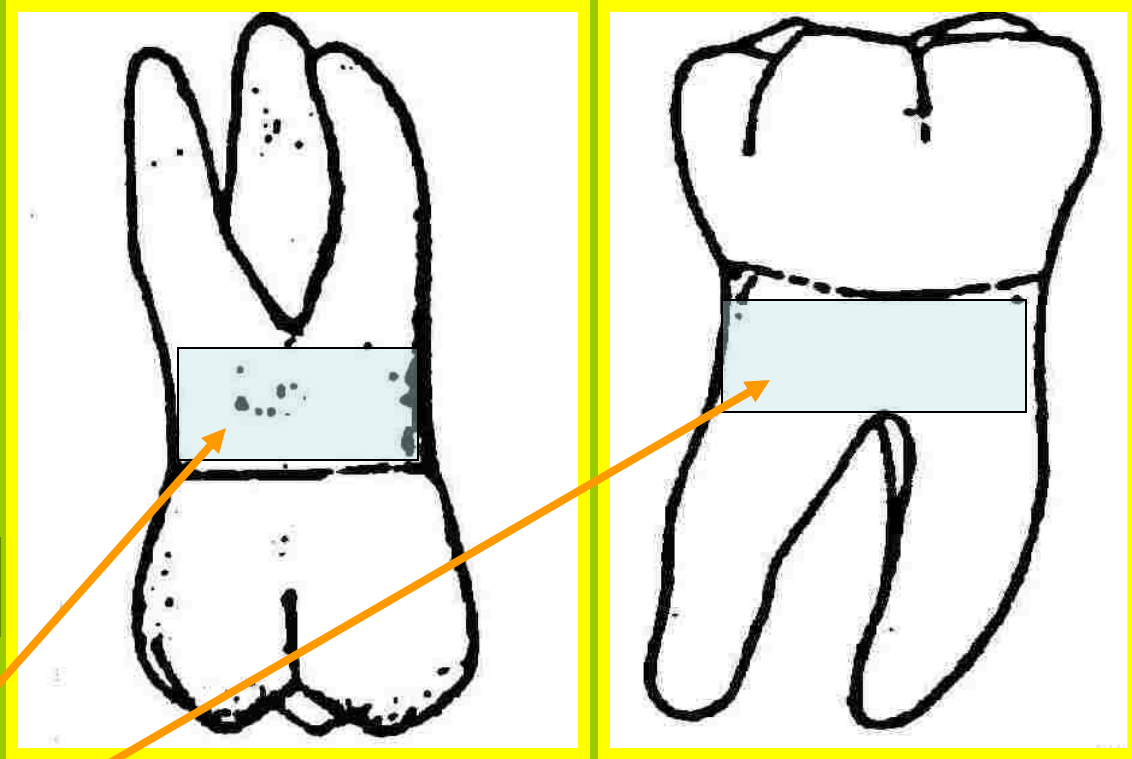


Teeth May Be Divided According To The Number Of Roots



Single rooted teeth

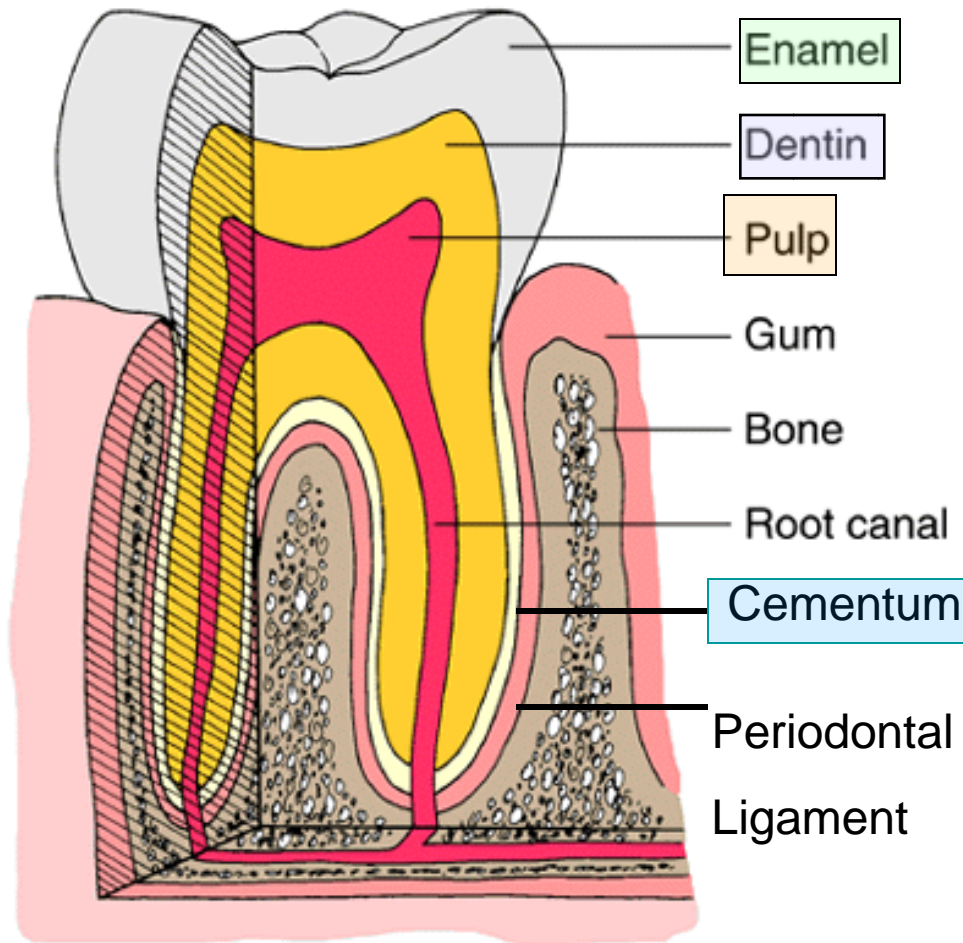
The undivided portion of the root is called:
Root Trunk.



Multirooted teeth

Tooth Anatomy

2- Micro-anatomy of the tooth



-Three calcified tissues:

Enamel

Dentin

Cementum

+ One soft specialized
connective tissue:

Pulp.

SUMMARY

Enamel: Covers, Most Mineralized, Yellowish White.

Cementum: Covers, Medium For The Attachment, Dull Yellow, Thickness.

Dentin: Surrounds The Pulp Cavities, Underlying The Enamel And The Cementum, Yellow.

Pulp: Housed In The Pulp Cavity, Soft Tissue, Supply.

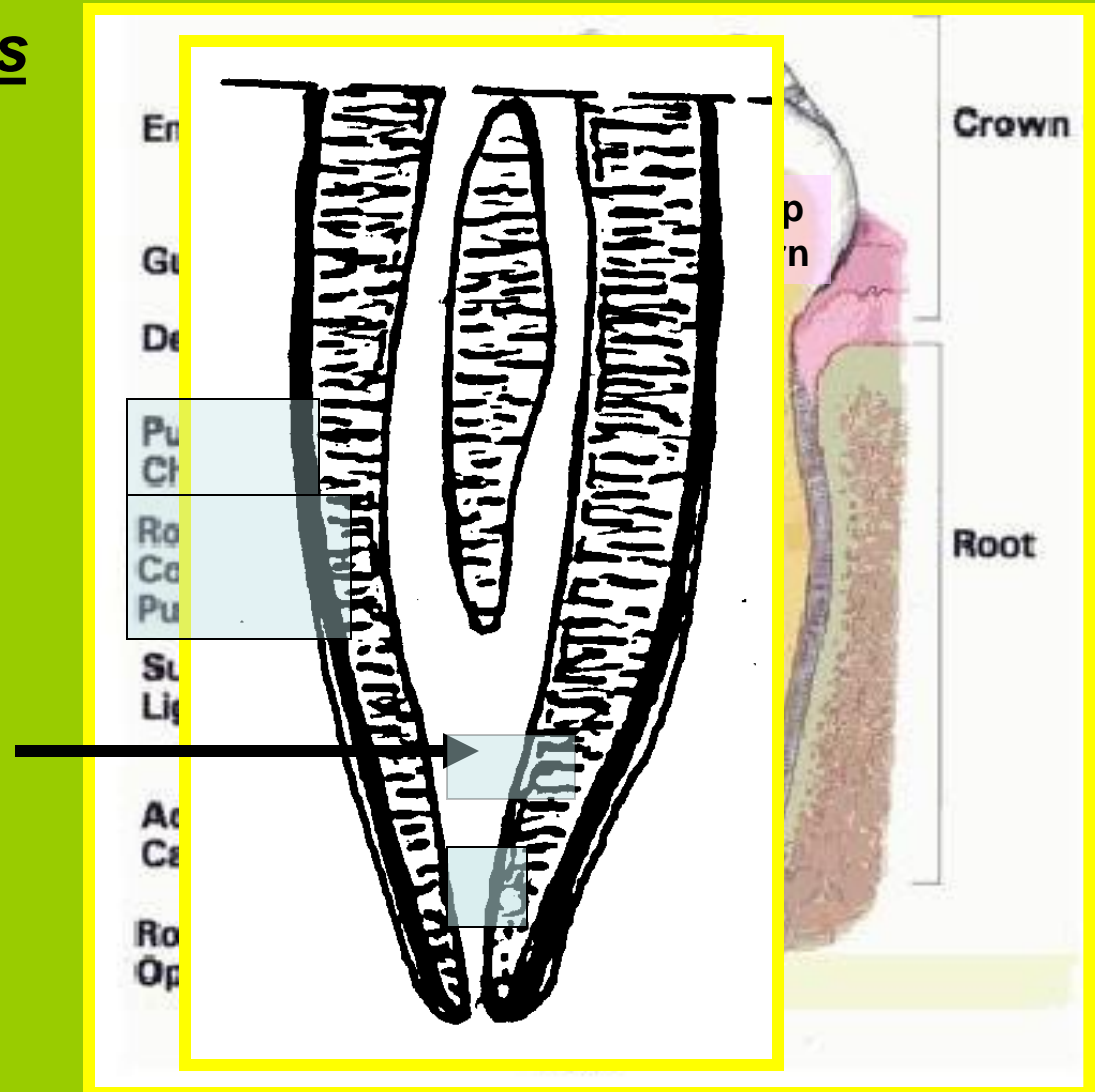
Anatomy Of The Pulp Cavity

Consists Of Two Parts

1 - Pulp chamber
+ pulp horns

2 - Root canal
+ apical foramen
+ accessory canals

Note: Many roots may be formed with more than one canal, which may end in a common foramen.



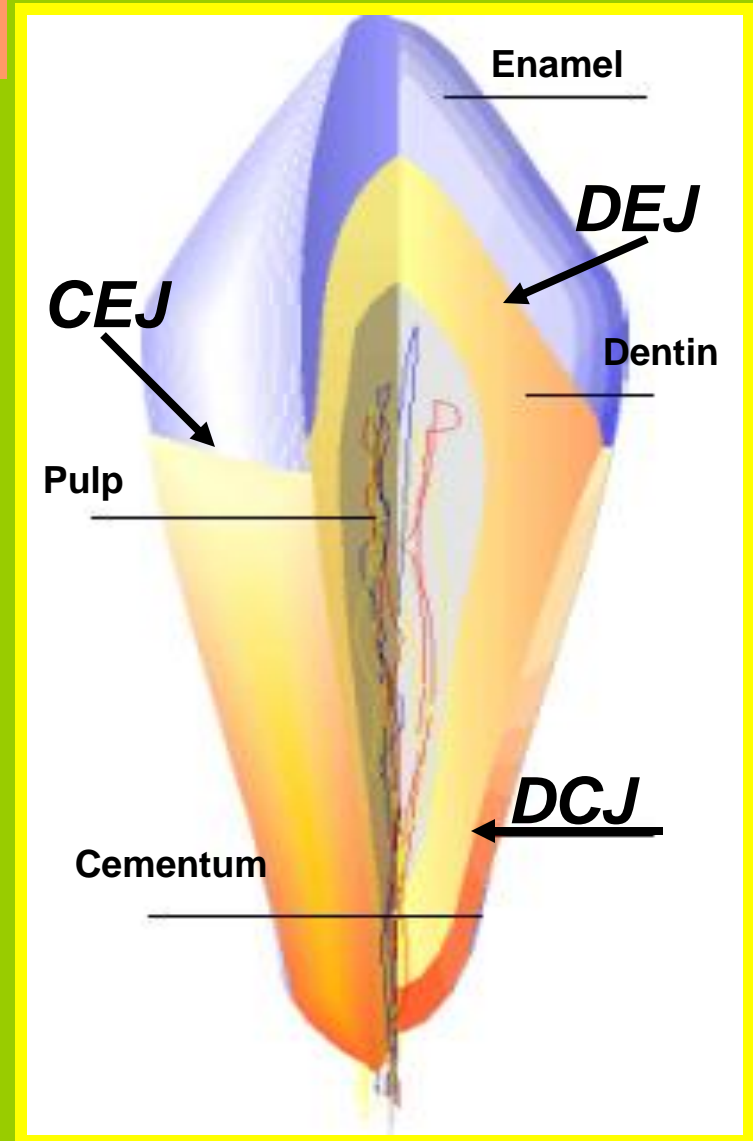
Junctions Of Tooth Tissues

There Are Three Sites Of Junction

1- Cemento-enamel junction
(CEJ):

2- Dentino-enamel junction
(DEJ):

3- Dentino-cemental junction
(DCJ):



The Periodontium

Is The Investing And Supporting Attachment System Of Teeth.

It consists of:

Two Soft Tissues

1- Gingiva

The Oral Mucous Membrane, Which Covers The Neck Of The Tooth And Part Of The Alveolar Bone

2- Periodontal Ligament

Strong Ligament that Attaches The Tooth To The Alveolar Bone

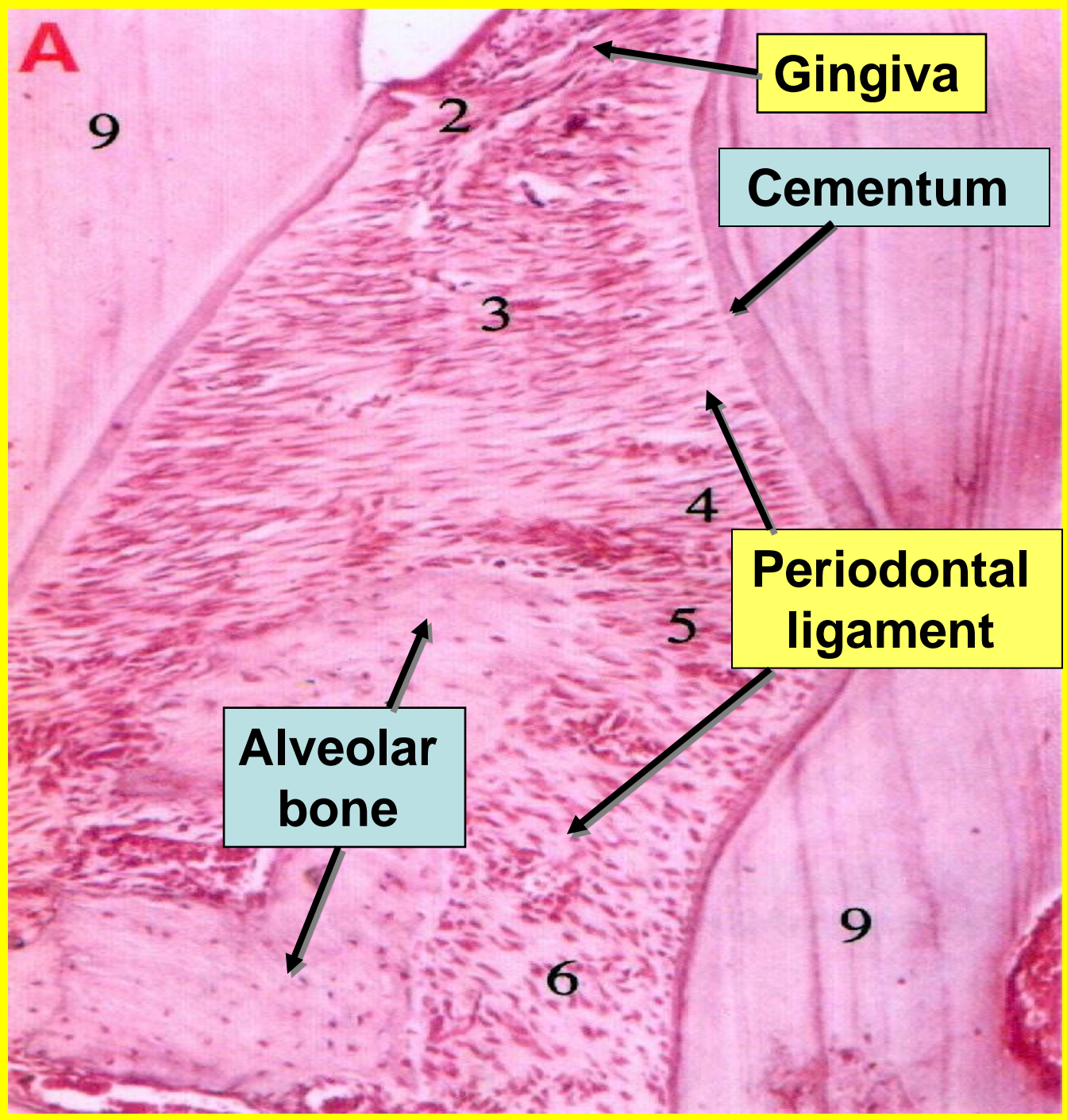
Two Hard Tissues

1- Cementum

Covers The Anatomical Root Of The Tooth

2- Alveolar Bone

The Bone Of The Jaw That Surrounds The Root Of The Tooth



A

9

2

3

4

5

6

9

Gingiva

Cementum


**Periodontal
ligament**

**Alveolar
bone**

Functions Of Teeth

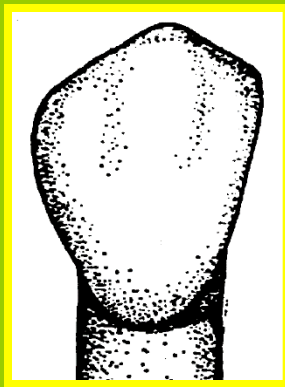
1- Mastication: *It is the most important function of the teeth. The teeth are designed to perform this function.*

Incisors



**Chisel like
Cutting or
incising**

Canine




**Wedge like
Cutting and
tearing**

Premolars



**At least two
projections
(cusps).
Tearing and
grinding**

Molars



**Multiple projections
(cusps)
Grinding**

2- Appearance:

- Well arranged clean teeth with proper alignment give nice appearance to the face.
- Teeth give support to the facial expressions.

3- Speech: Teeth are important for clear pronunciation and for production of sound.

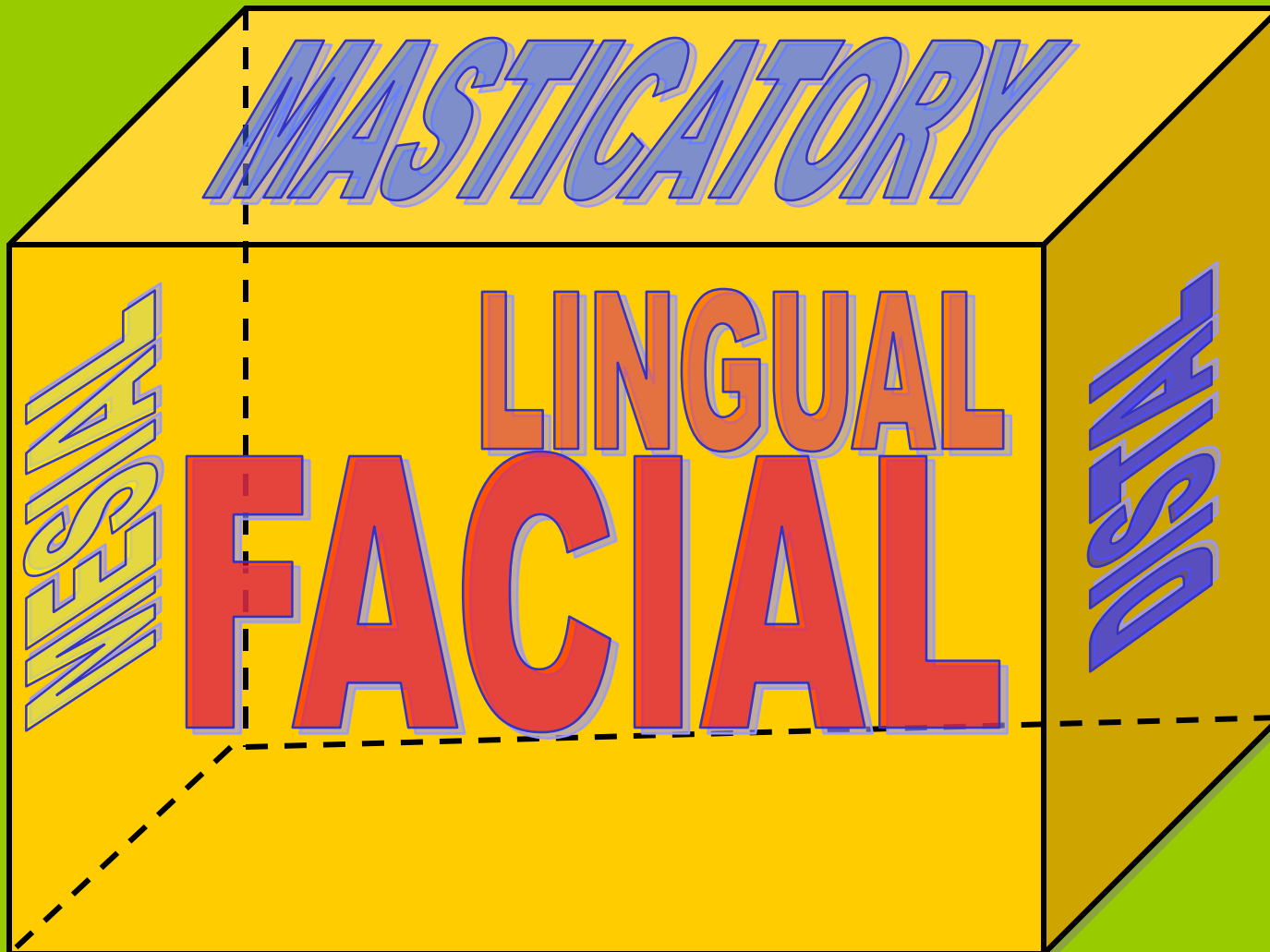
4- Growth of jaws:

The teeth play a role in the growth of the jaws in some periods of life.

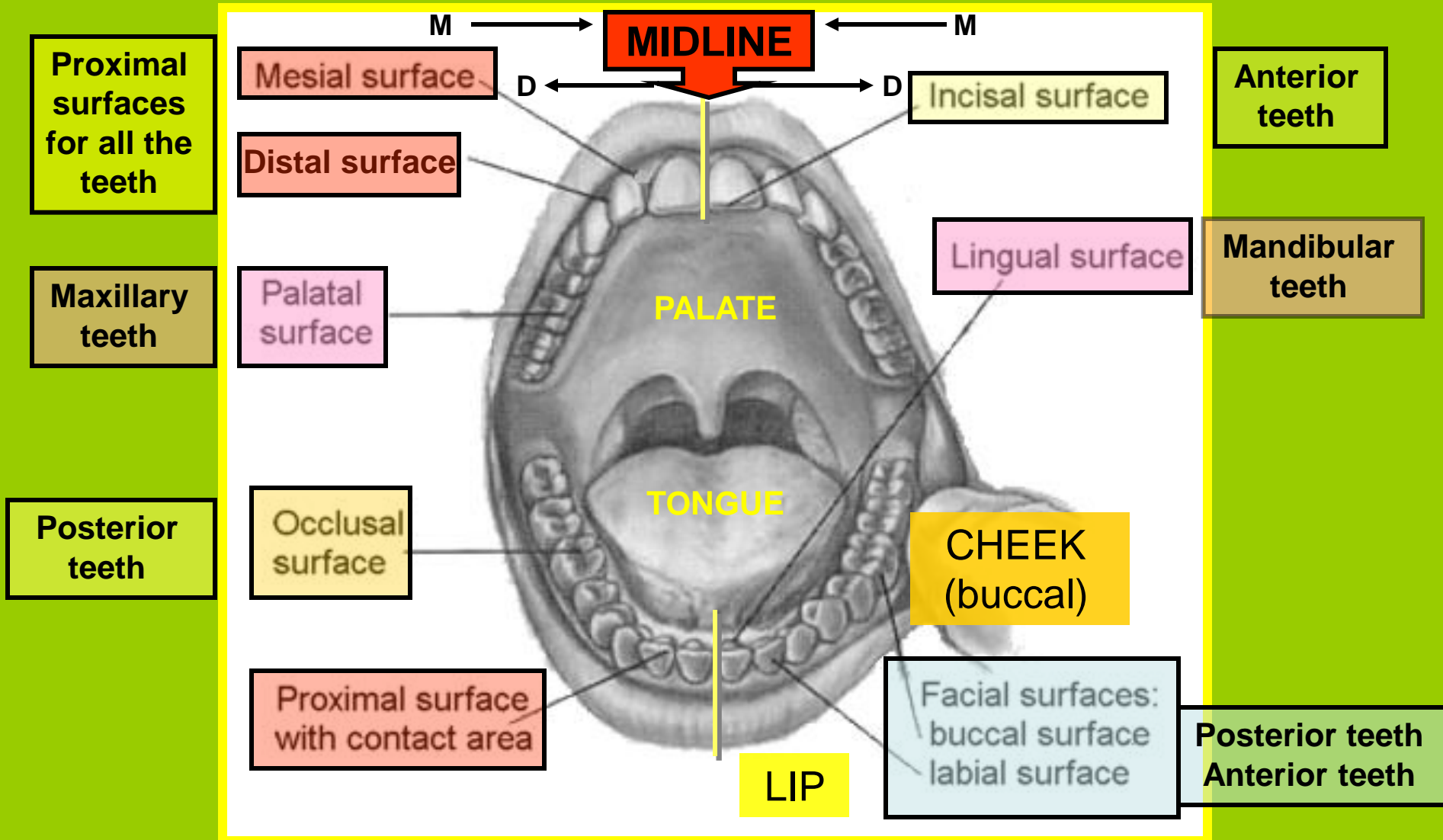


Tooth Surfaces

Each Tooth Has Five Surfaces Like A Box With 4 Sides And A Roof.



The Surfaces Are Identified By The Relationship To Other Orofacial Structures



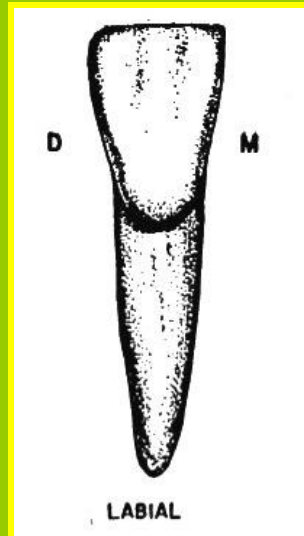

FACIAL

LABIAL

**TOWARDS
THE LIP**

FOR

**ANTERIOR
TEETH**


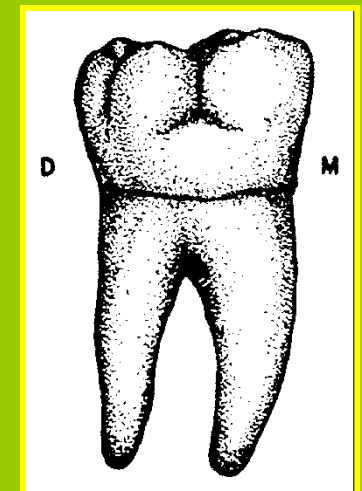
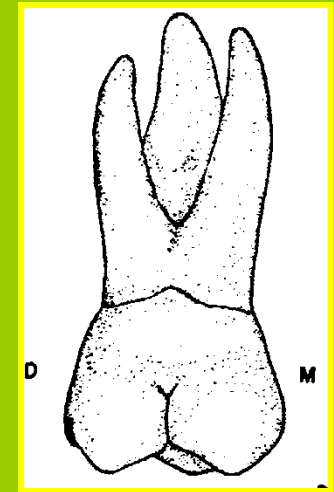


OR BUCCAL

**TOWARDS
THE CHEEK**

FOR

**POSTERIOR
TEETH**



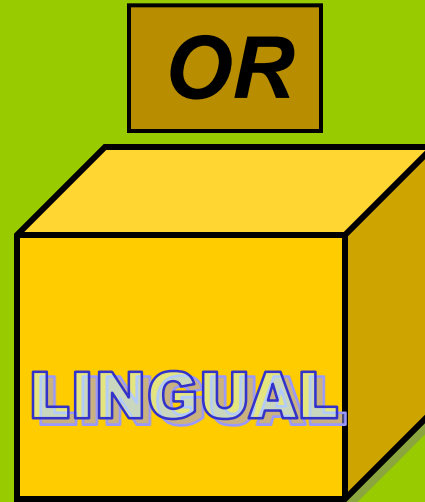
LINGUAL

PALATAL

**TOWARDS
THE PALAT**

**FOR MAXILLARY
TEETH**

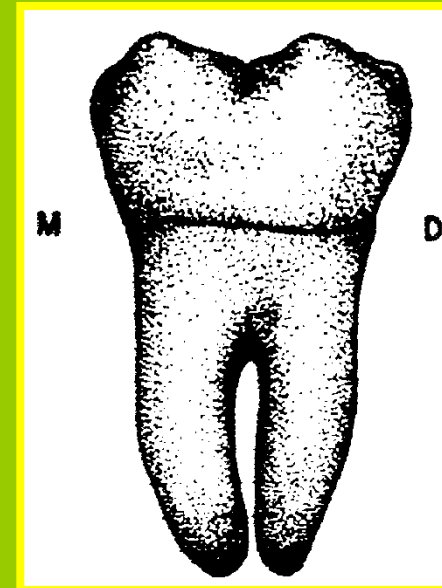

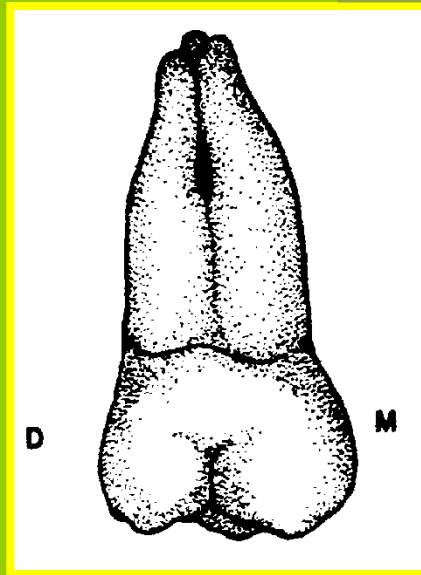
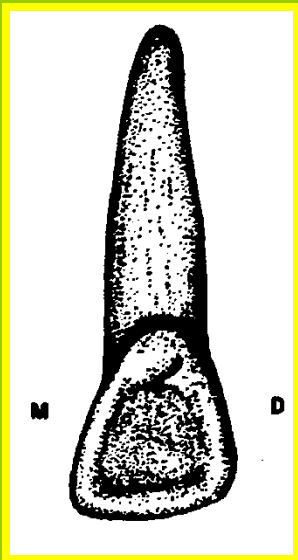
OR



LINGUAL

**TOWARDS
THE TONGUE**

**FOR MANDIBULAR
TEETH**



PROXIMAL

MESIAL

&

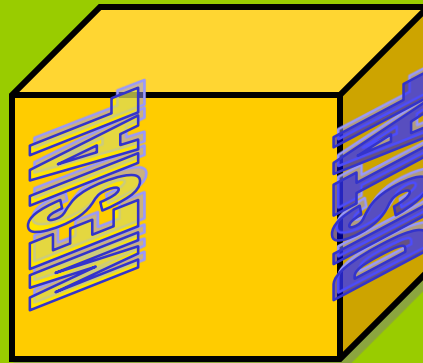
DISTAL

TOWARDS THE MIDLINE


AWAY FROM THE MIDLINE



Mesial



FOR ALL THE
TEETH




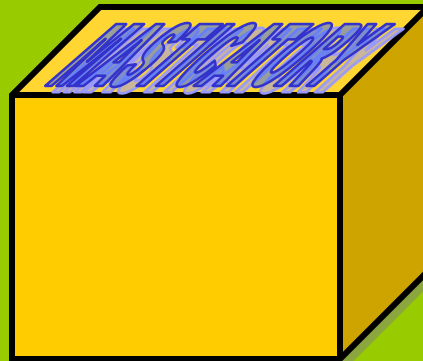
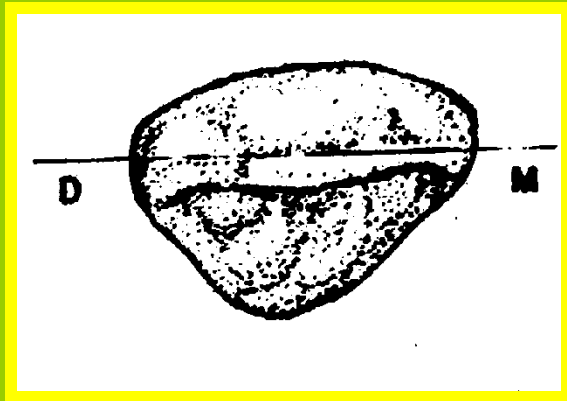
Distal

MASTICATORY

INCISAL

OR

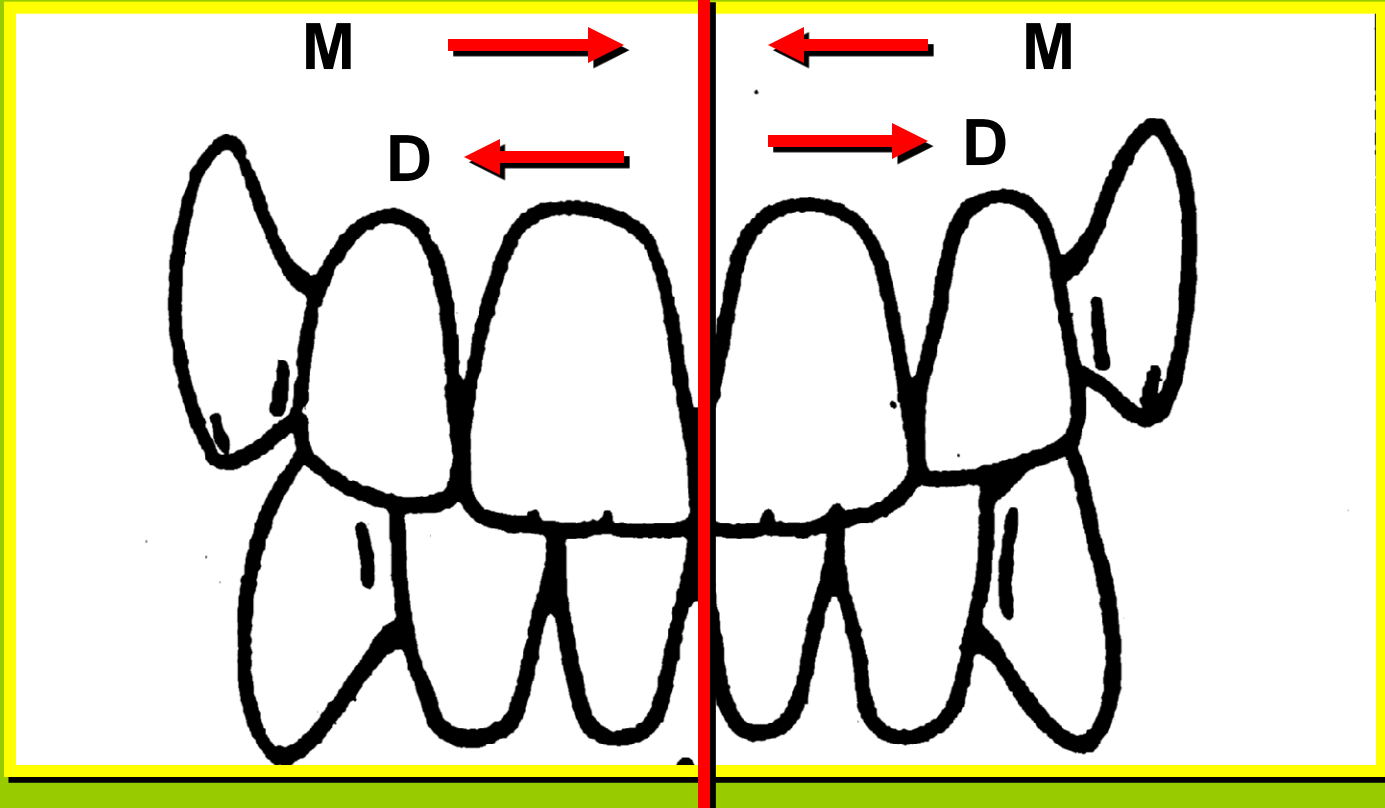
OCCLUSAL



FOR ANTERIOR TEETH

FOR POSTERIOR TEETH

MIDLINE

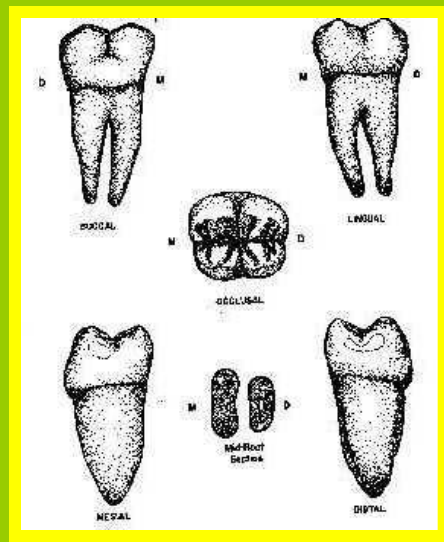
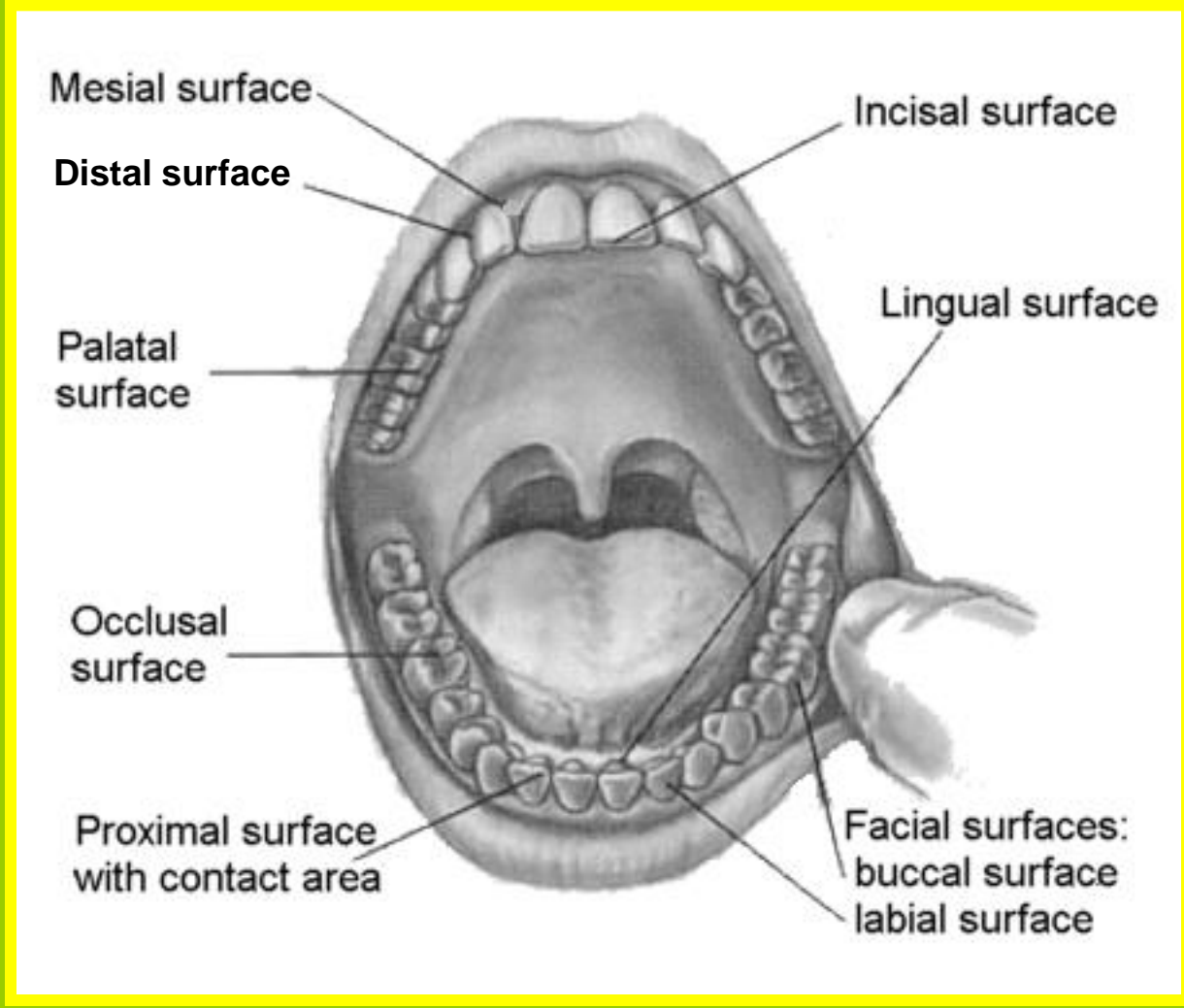
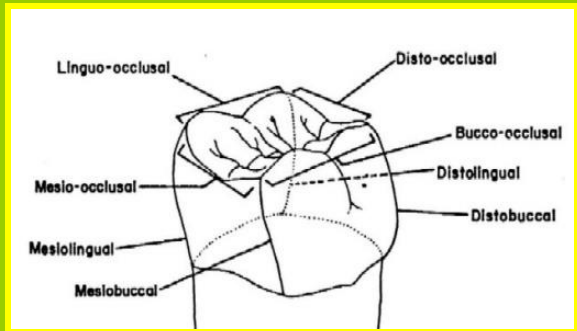


M = MESIAL SURFACES

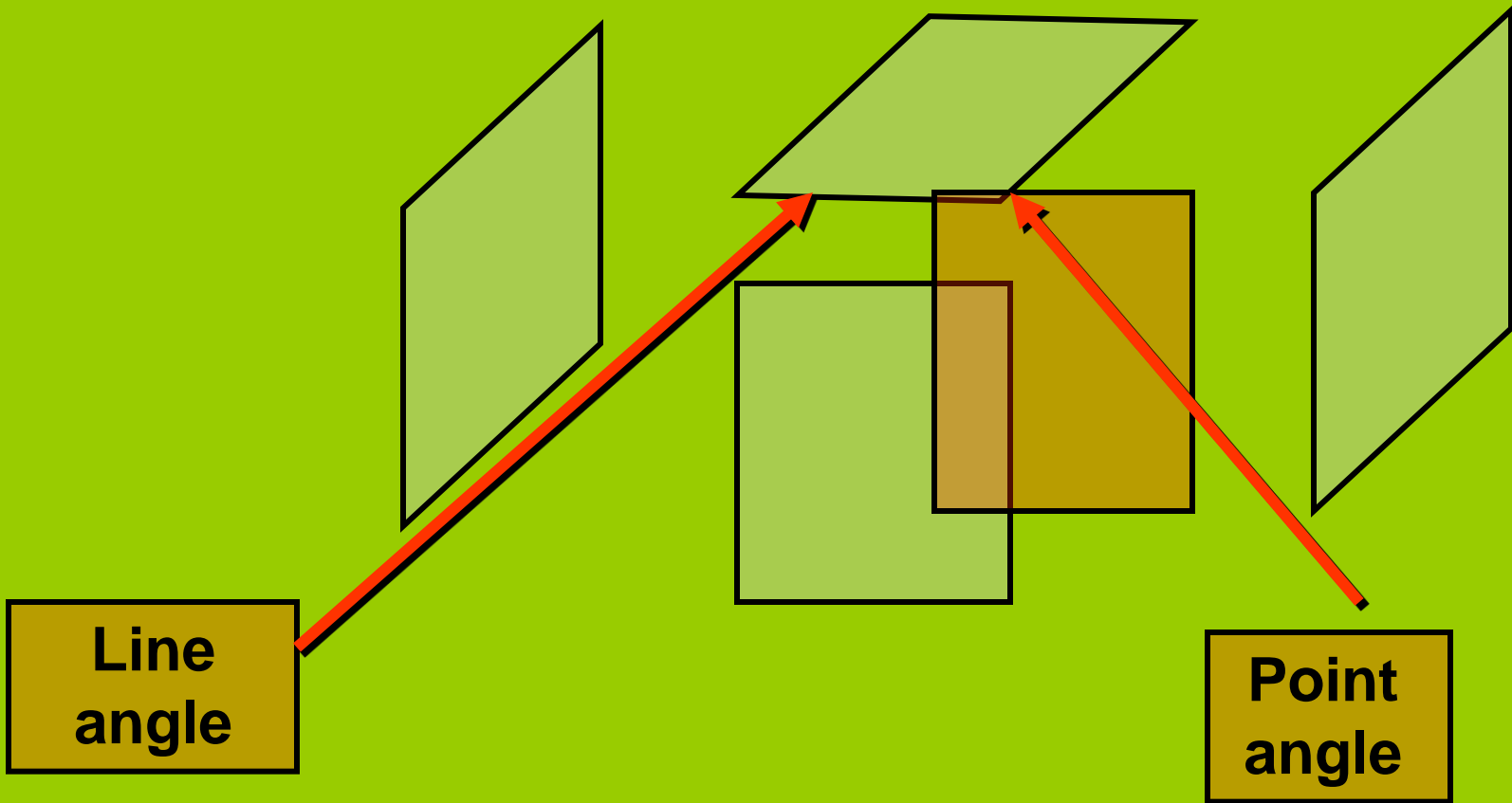
D = DISTAL SURFACES

So The Tooth Surfaces Are:

Facial.
Lingual.
Mesial. Distal.
Masticatory.



Line And Point Angles



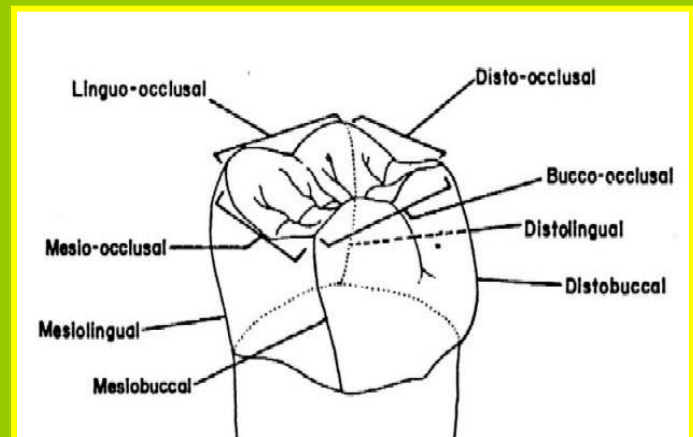
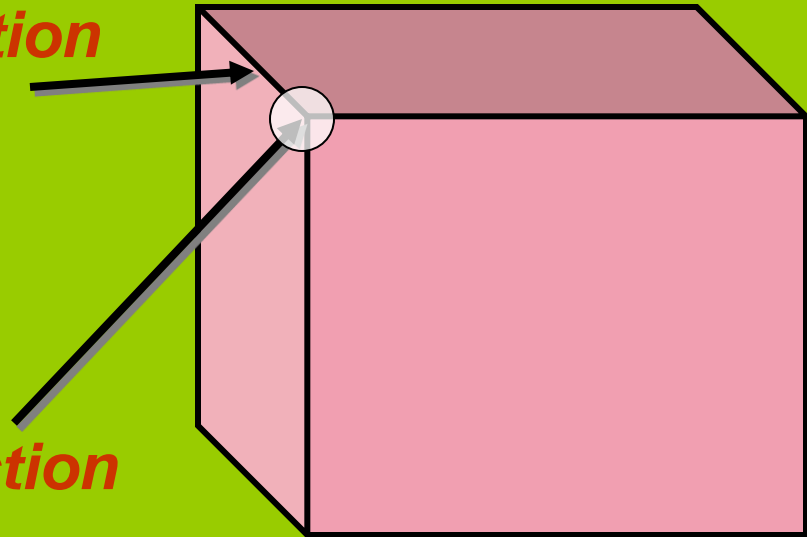
Line And Point Angles

Line angle:

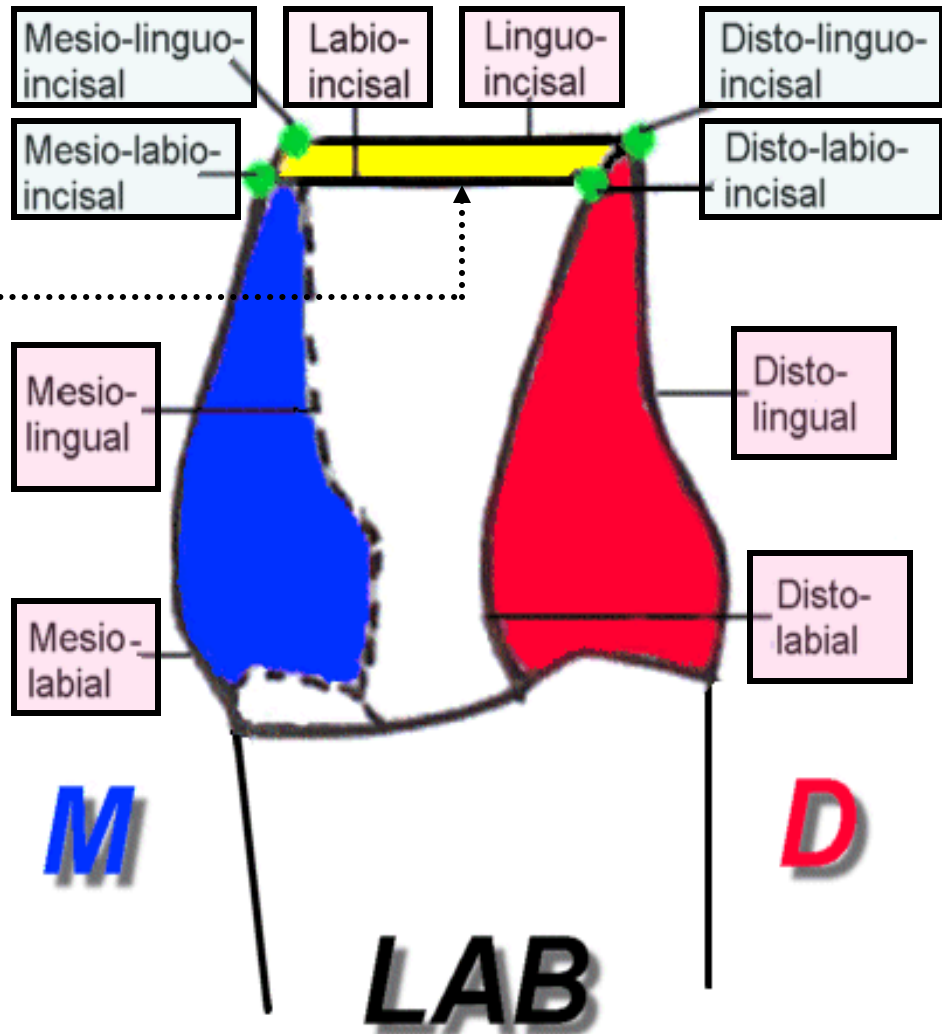
It is formed by the junction of two surfaces and its name is derived from both surfaces

Point angle:

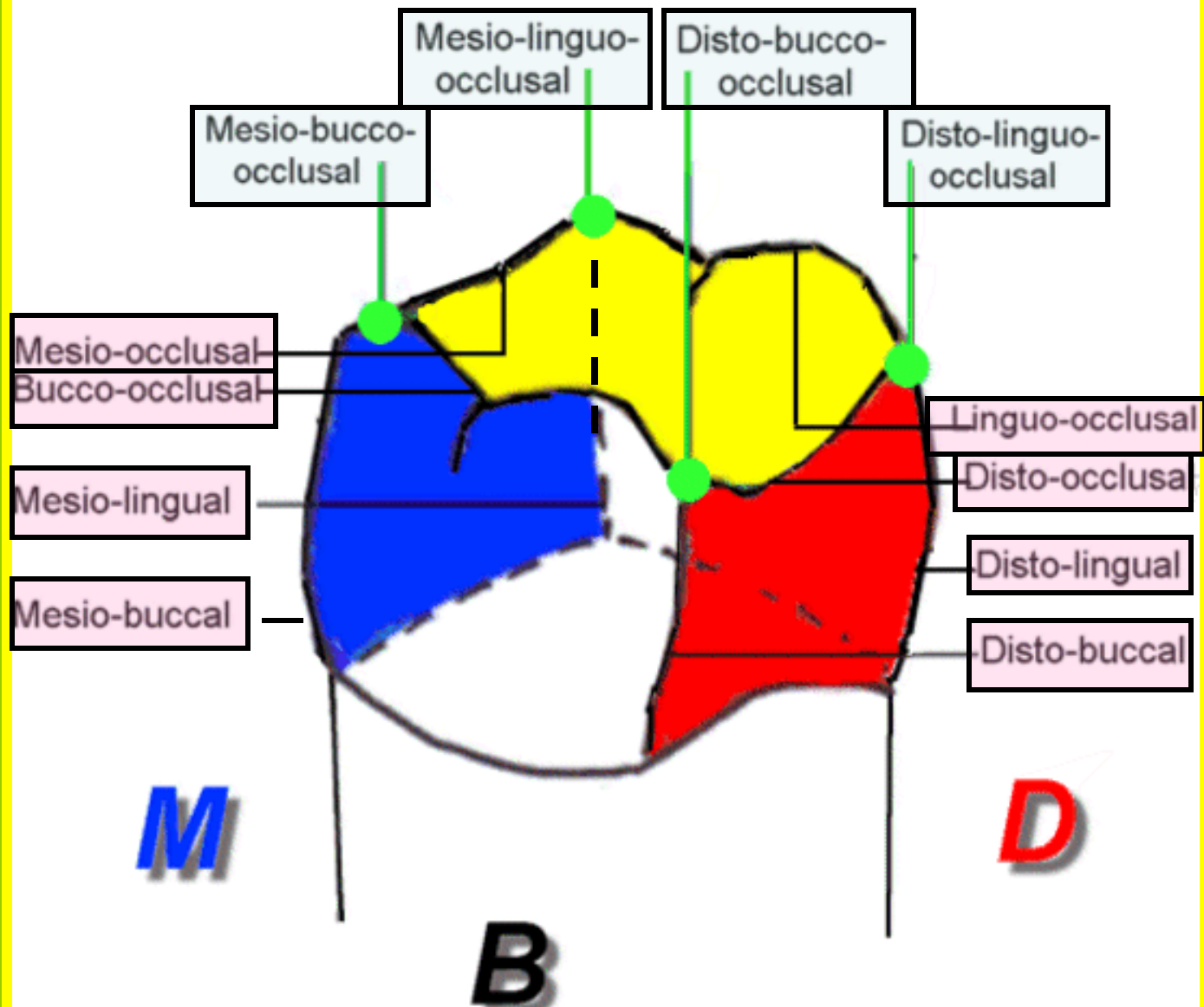
It is formed by the junction of three surfaces and its name is derived from these surfaces.



**Incisal
Edge**

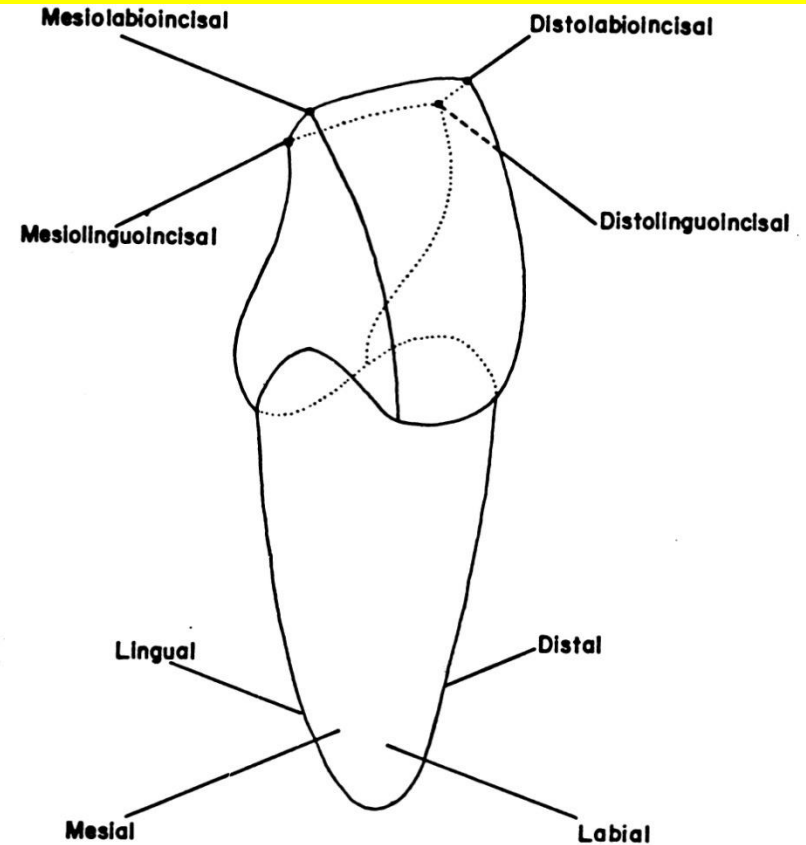
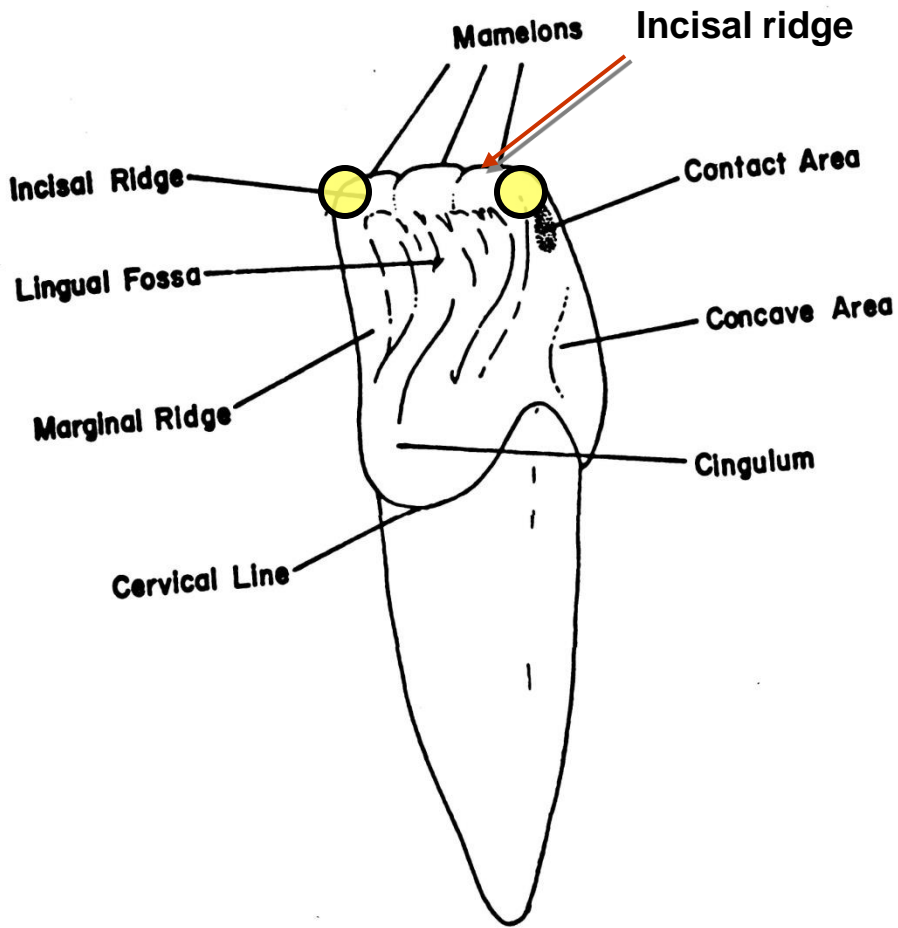


Line And Point Angles Of The Anterior Teeth



Line And Point Angles Of The Posterior Teeth

Note:



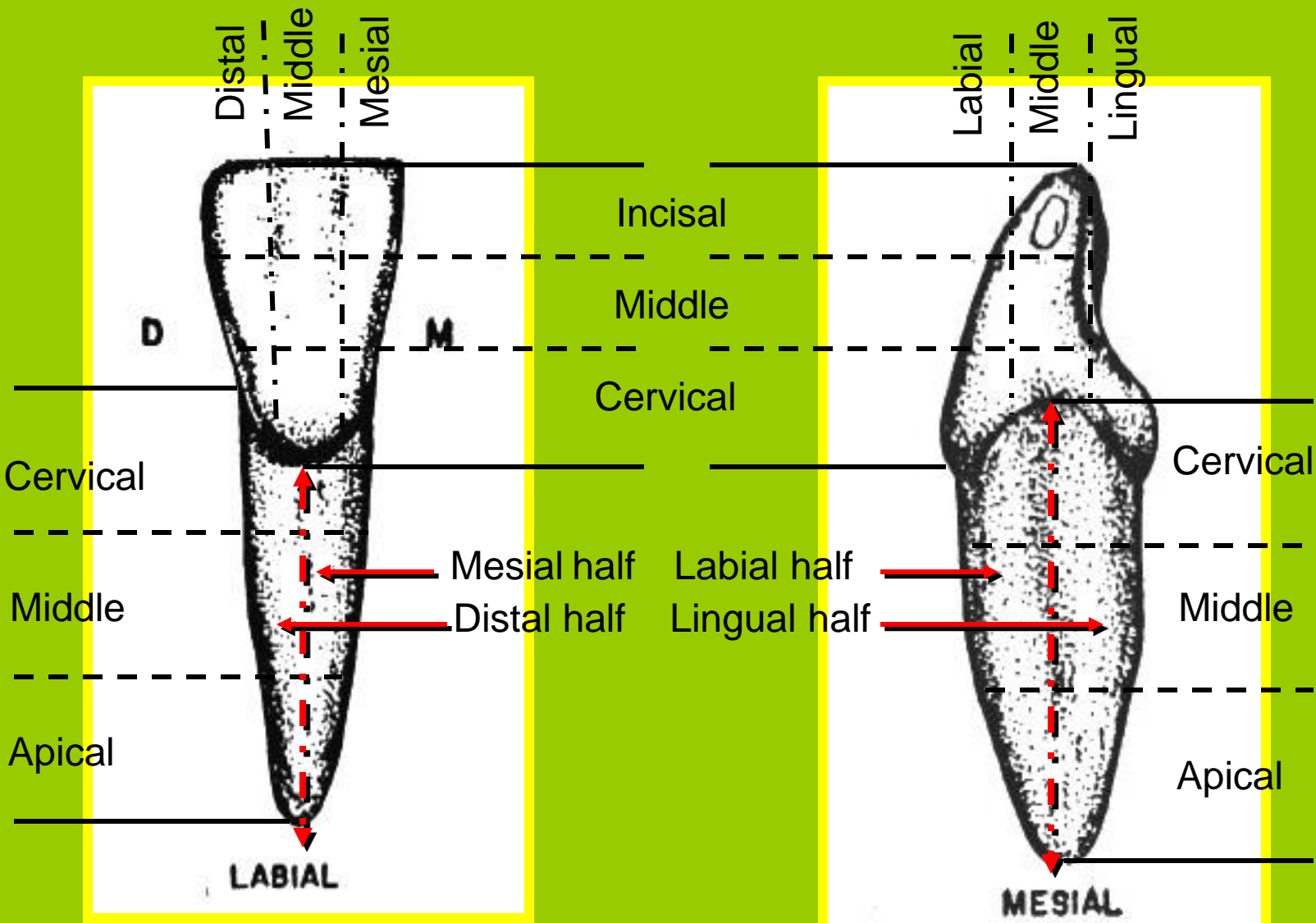
Point angles of anterior teeth.

Note: The **anterior teeth have fewer line angles** because the meeting of the mesial and distal line surfaces with incisal ridge are rounded ○, so the **mesio-incisal** and **disto-incisal** line angles are practically not exist. .

Division Into Thirds

For descriptive purposes (to locate the anatomical landmarks):

- Crown surfaces could be divided ***horizontally or vertically*** into three portions or thirds,
- The root could be divided into thirds **horizontally**, while **vertically** into halves by the root axis line { labial (buccal) & lingual **and/or** mesial & distal }.



Tooth Identification System

1) Palmer Notation System:

It represents the four quadrants of the dentition as if you facing the patient.

In upper right
In lower right

In upper left
In lower left

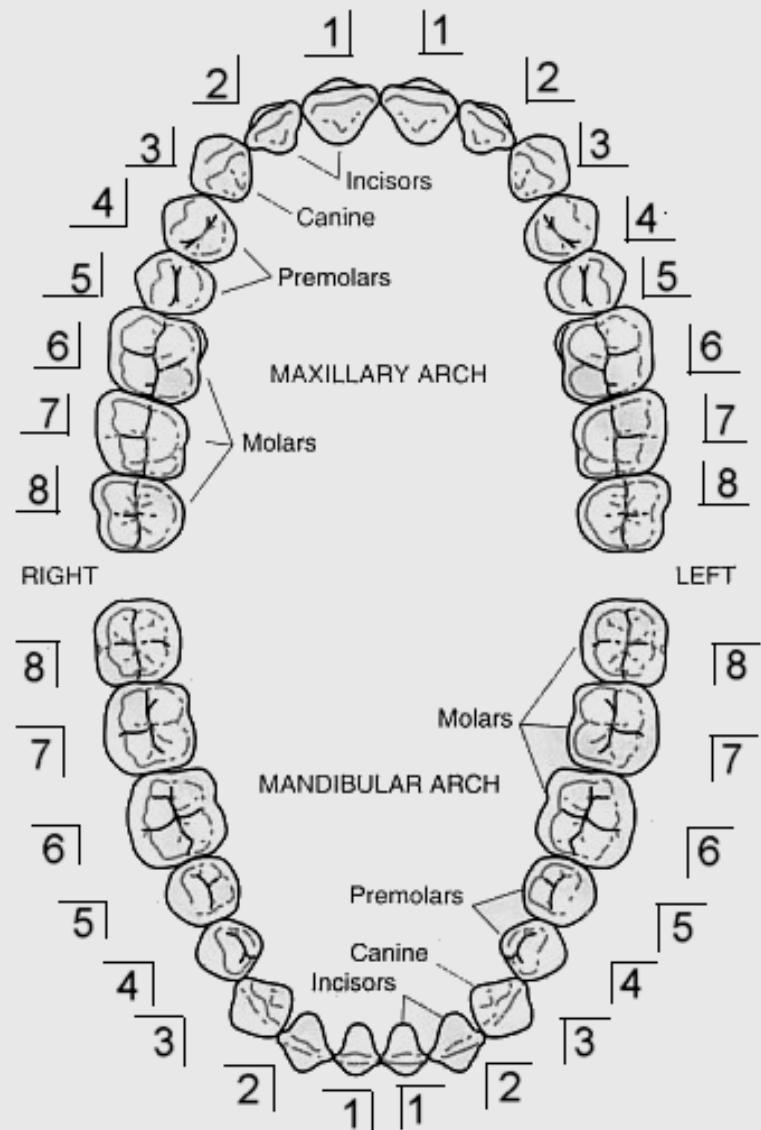
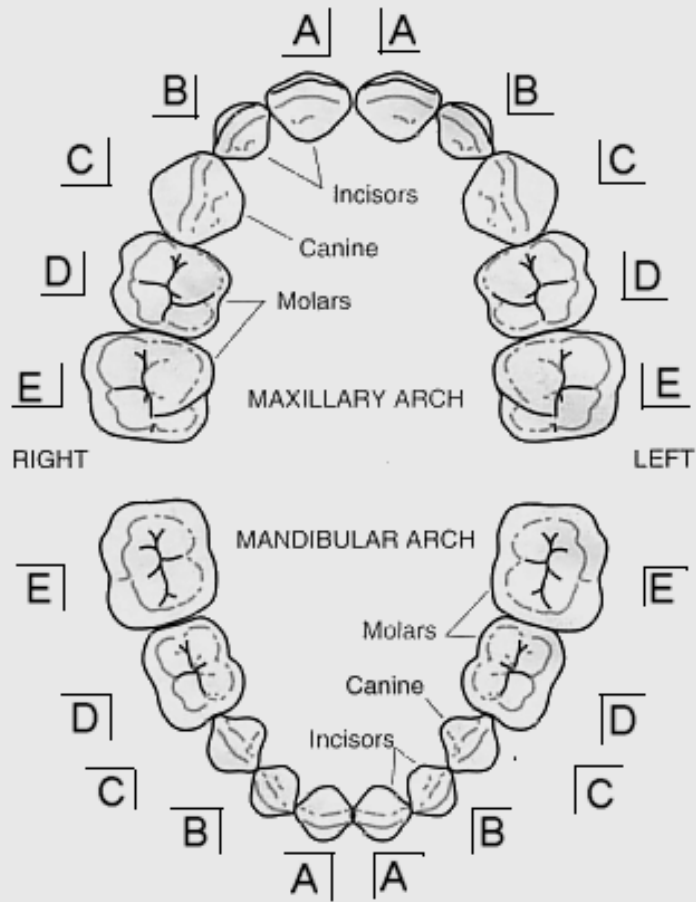
The **permanent teeth** are numbered from **1-8** on each side from the midline.

Upper right	Upper left
8 7 6 5 4 3 2 1	1 2 3 4 5 6 7 8
<hr/>	<hr/>
8 7 6 5 4 3 2 1	1 2 3 4 5 6 7 8
Lower right	Lower left

The **deciduous teeth** are lettered from **A-E** on each side from the midline.

Upper right	Upper left
E D C B A	A B C D E
<hr/>	<hr/>
E D C B A	A B C D E
Lower right	Lower left

This system utilizes simple brackets to represent the 4 quadrants of the dentition as if you facing the patient.



2- The international numbering system (the two digit system)

The teeth are designed by using two-digit systems:

- a. The **first digit** of the code is located at the left side of the number and indicates the **quadrant**.

In the permanent dentition.

U.R.	1	2	U.L.
L.R.	4	3	L.L.

In the deciduous dentition.

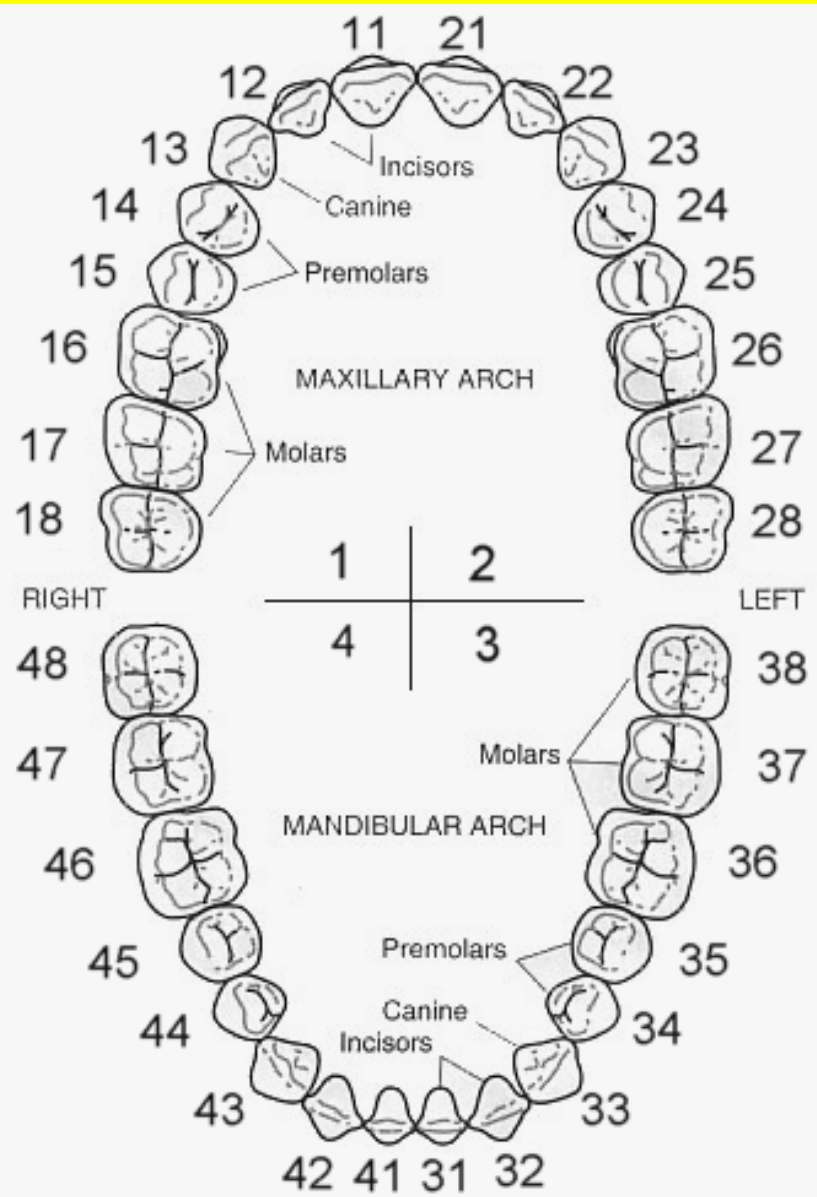
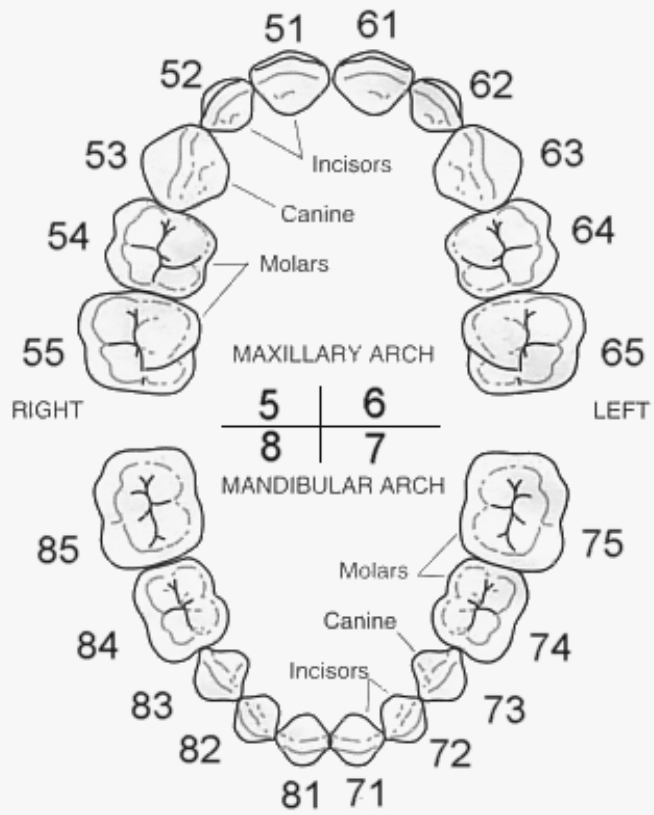
U.R.	5	6	U.L.
L.R.	8	7	L.L.

- b- The **second digit** is located at the right side of the number and indicates the **number of the tooth** in the quadrant.

The two digits should be pronounced separately.

Permanent teeth															
18	17	16	15	14	13	12	11	21	22	23	24	25	26	27	28
48	47	46	45	44	43	42	41	31	32	33	34	35	36	37	38

Deciduous teeth									
55	54	53	52	51	61	62	63	64	65
85	84	83	82	81	71	72	73	74	75



3) The universal numbering system (American numbering system):

The number is always preceded by the **sign #** to designate that the system is used for universal system.

Permanent teeth (1 – 32)

1	2	3	4	5	6	7	8	9	10	11	12	13	14	15	16
32	31	30	29	28	27	26	25	24	23	22	21	20	19	18	17

Deciduous teeth (1 – 20)

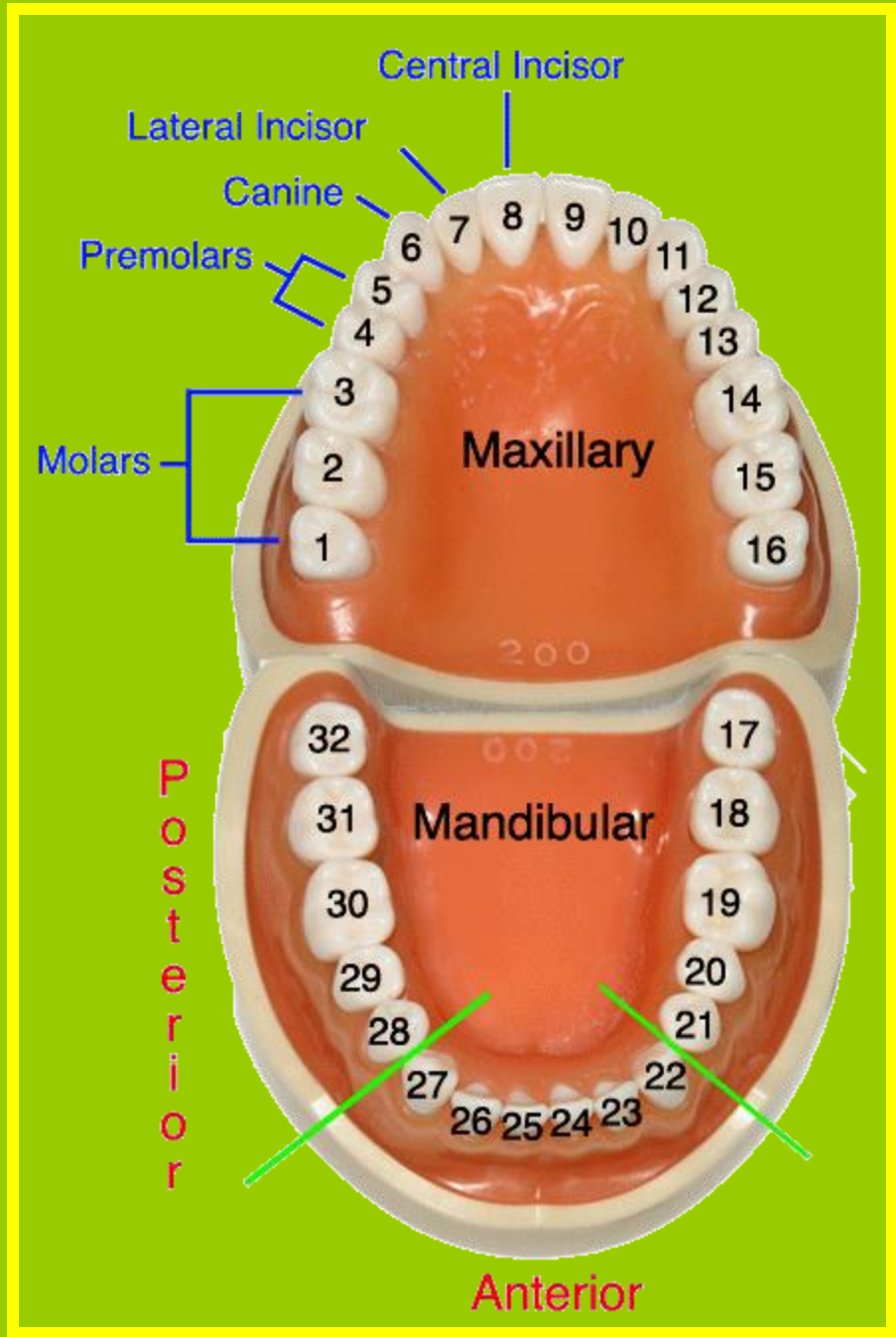
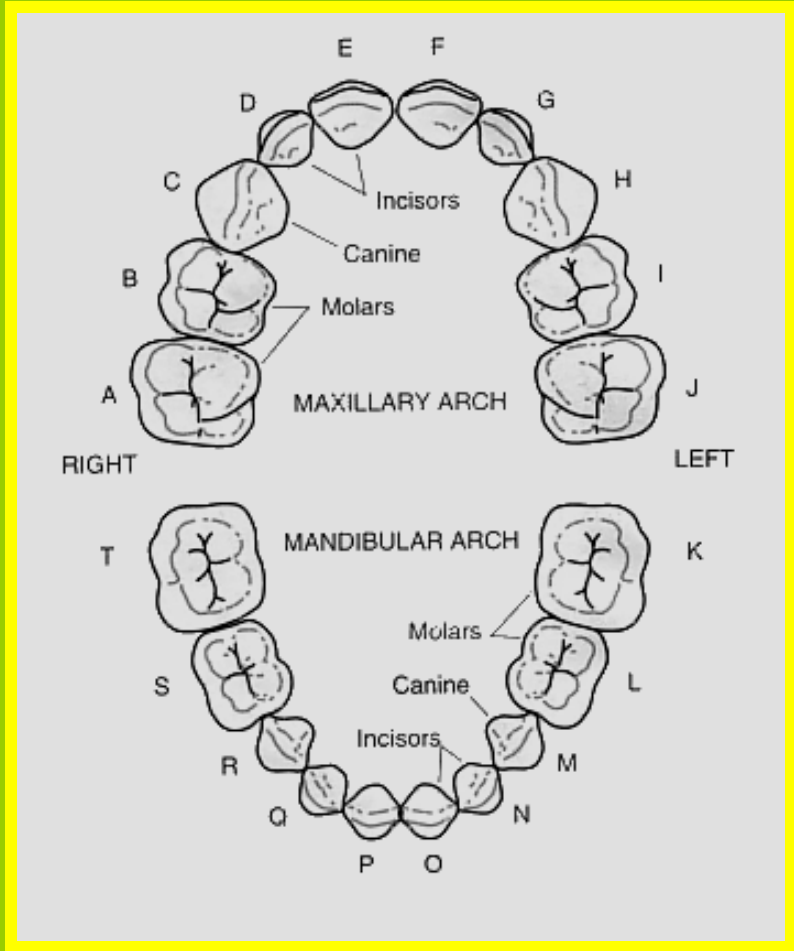
1	2	3	4	5	6	7	8	9	10
20	19	18	17	16	15	14	13	12	11

Litter d is added as a suffix to each number e.g. #10d for deciduous upper left 2nd molar

Deciduous teeth (A - T)

A	B	C	D	E	F	G	H	I	J
T	S	R	Q	P	O	N	M	L	K

Another system (A -----J T -----K)



	Tooth	Universal		Palmer Notation		The digit system	
		Right	Left	Right	Left	Right	Left
Deduous Dentition Maxillary Teeth	Central incisor	E	F	<u>A</u>	<u>A</u>	51	61
	Lateral incisor	D	G	<u>B</u>	<u>B</u>	52	62
	Canine	C	H	<u>C</u>	<u>C</u>	53	63
	First molar	B	I	<u>D</u>	<u>D</u>	54	64
	Second molar	A	J	<u>E</u>	<u>E</u>	55	65
Deduous Dentition Mandibular Teeth	Central incisor	P	O	<u>A</u>	<u>A</u>	81	71
	Lateral incisor	Q	N	<u>B</u>	<u>B</u>	82	72
	Canine	R	M	<u>C</u>	<u>C</u>	83	73
	First molar	S	L	<u>D</u>	<u>D</u>	84	74
	Second molar	T	K	<u>E</u>	<u>E</u>	85	75
Permanent Dentition Maxillary Teeth	Central incisor	8	9	<u>1</u>	<u>1</u>	11	21
	Lateral incisor	7	10	<u>2</u>	<u>2</u>	12	22
	Canine	6	11	<u>3</u>	<u>3</u>	13	23
	First premolar	5	12	<u>4</u>	<u>4</u>	14	24
	Second premolar	4	13	<u>5</u>	<u>5</u>	15	25
	First molar	3	14	<u>6</u>	<u>6</u>	16	26
	Second molar	2	15	<u>7</u>	<u>7</u>	17	27
	Third molar	1	16	<u>8</u>	<u>8</u>	18	28
Permanent Dentition Mandibular Teeth	Central incisor	25	24	<u>1</u>	<u>1</u>	41	31
	Lateral incisor	26	23	<u>2</u>	<u>2</u>	42	32
	Canine	27	22	<u>3</u>	<u>3</u>	43	33
	First premolar	28	21	<u>4</u>	<u>4</u>	44	34
	Second premolar	29	20	<u>5</u>	<u>5</u>	45	35
	First molar	30	19	<u>6</u>	<u>6</u>	46	36
	Second molar	31	18	<u>7</u>	<u>7</u>	47	37
	Third molar	32	17	<u>8</u>	<u>8</u>	48	38

ANATOMICAL LANDMARKS OF THE CROWN

CROWN ELEVATIONS

1. Lob

-Mamelones
-Cingulum
-Cusps

2. Tubercle

3. Ridges

Facial surf.

Ling. surf.

Occl. surf.

-Labial R.

-Buccal R.

-Cervical R.

-Incisal R.

-Cusp R.

-Lingual R.

-Marginal R.

(incisors & canines)

-Marginal R.

-Triangular R.

-Transverse R.

-Oblique R.

CROWN DEPRESSIONS

1. Development. Grooves

2. Supplement. Grooves

3. Fissure

4. Fossa

-Lingual
-Mesial triang.
-Distal triang.
-Central

5. Pits

6. Sulcus

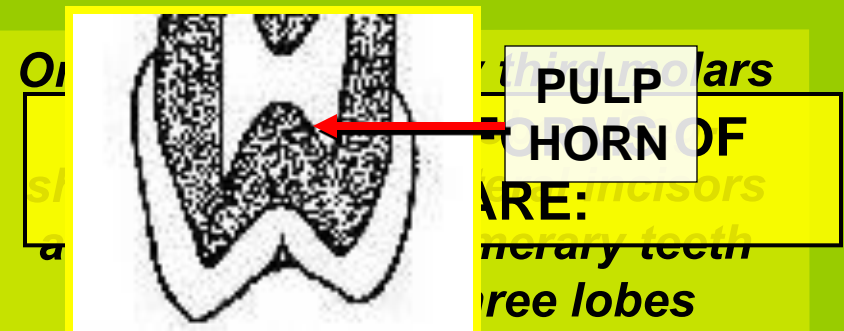
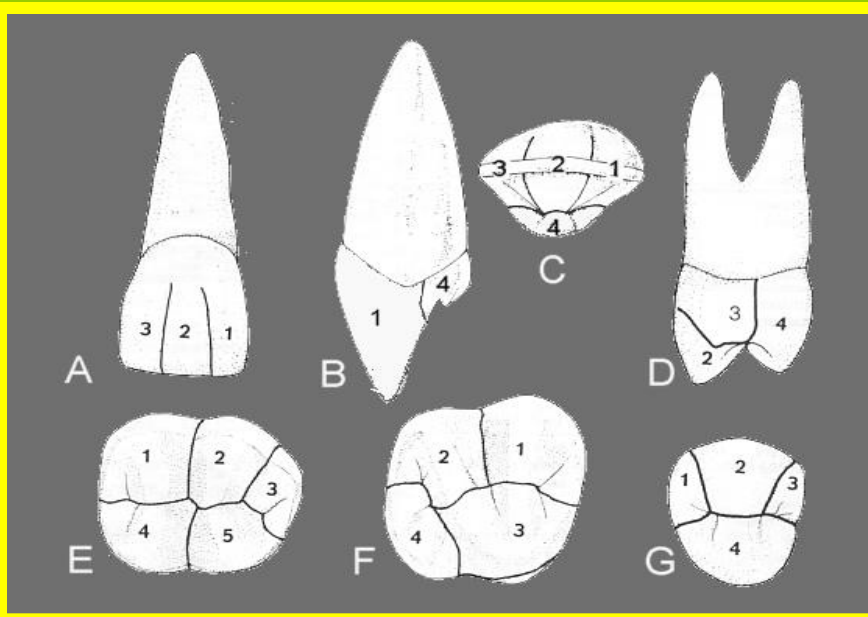
Anatomical Landmarks Of The Crown

A - Crown Elevations

(I) Lobe.

It is one of the primary centers of calcification and growth formed during the crown development. Each tooth begins to develop from four lobes or more.

The pulp chamber has pulp horns corresponding to these lobes.



1. Mamelones

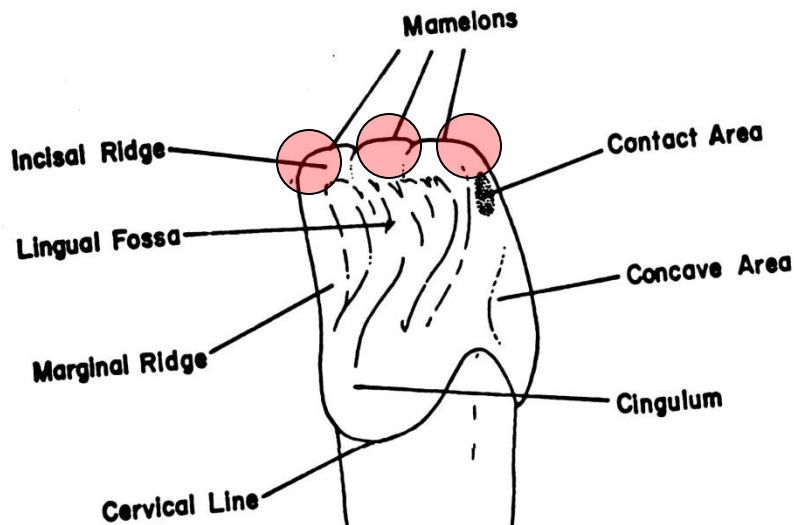
2. Cingulum

3. Cusps

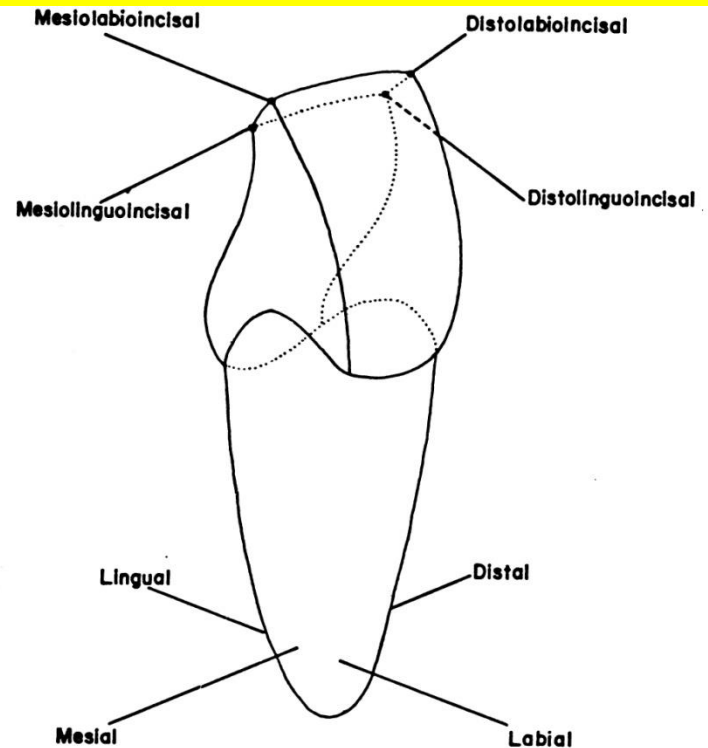
1. Mamelones:

They are three small round projections of enamel present in the incisal third of newly erupted incisors.

After normal use, eventually the mamelones wear down into a flat edge (attrition).



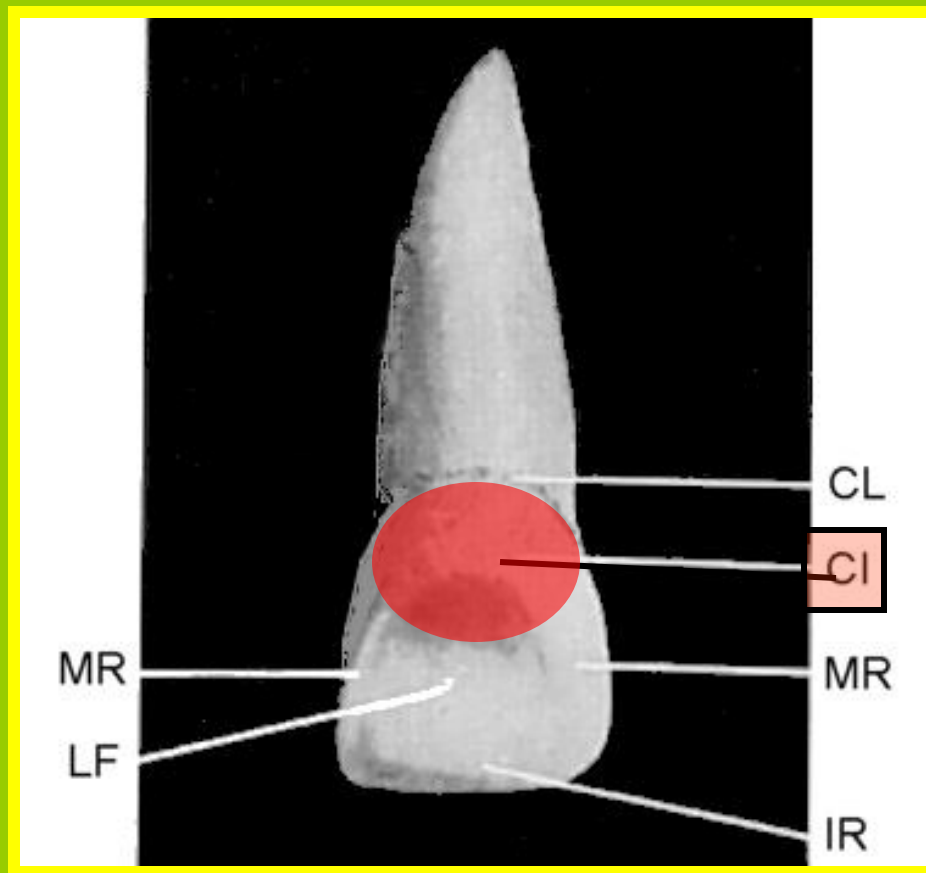
The pulp chamber has 3 pulp horns corresponding to these 3 mamelones



Point angles of anterior teeth.

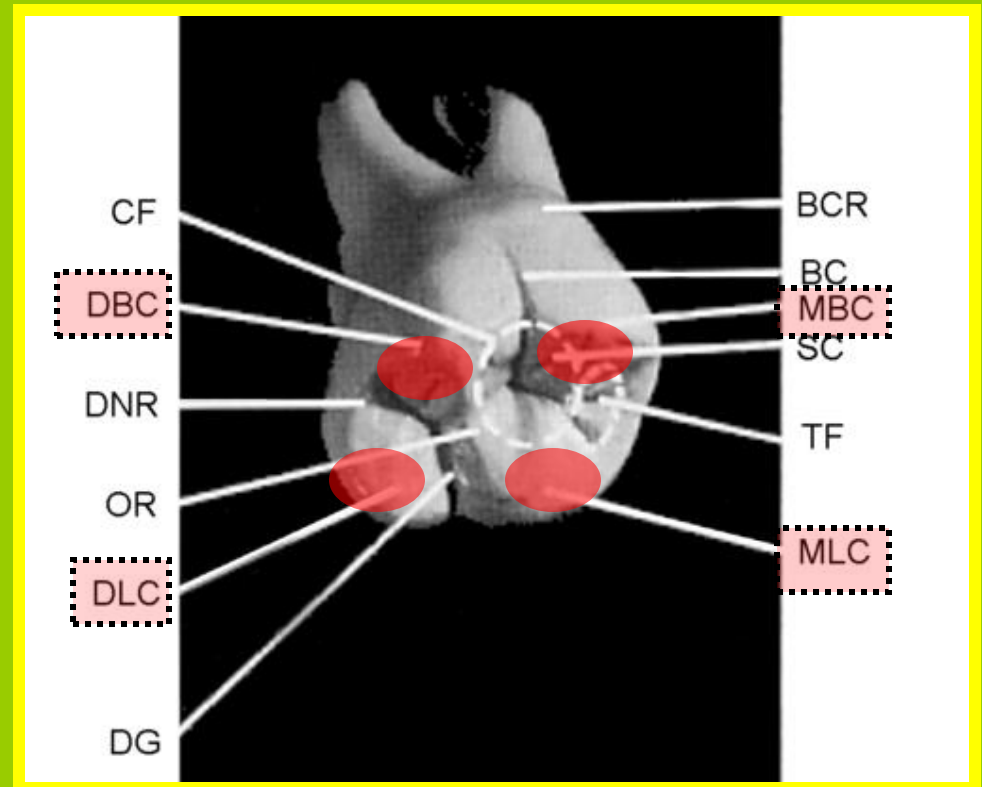
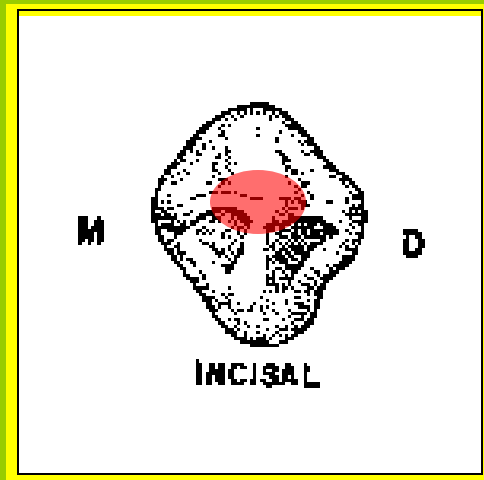
2.Cingulum:

It is the **enlargement or bulge** on the **cervical third** of **lingual surface** of the crown in anterior teeth (incisors and canines). It is also called the **lingo-cervical ridge**



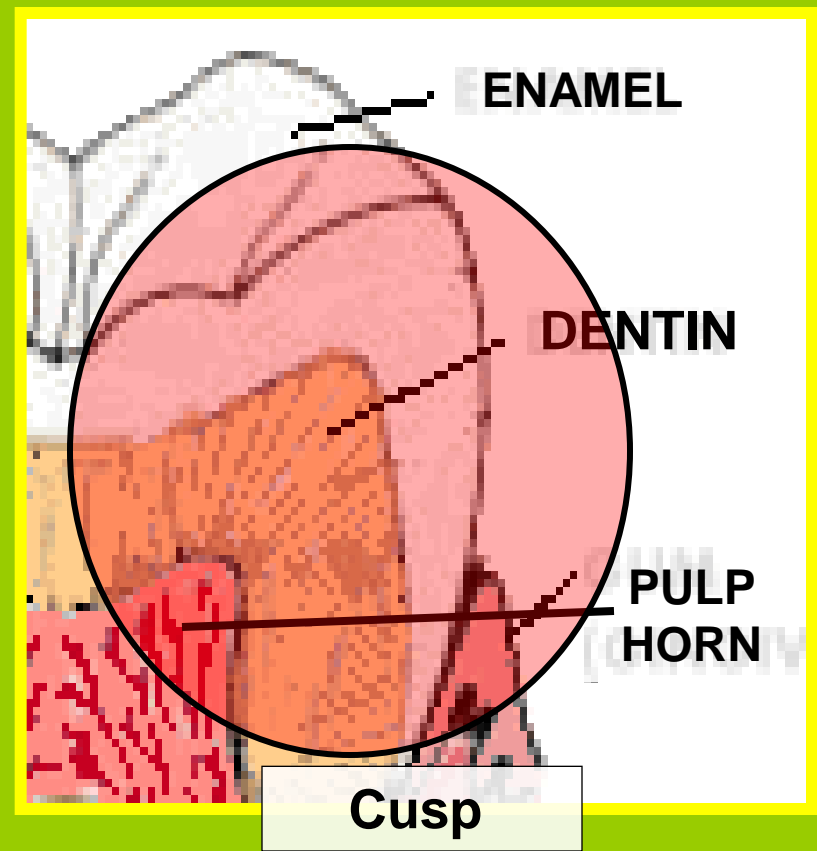
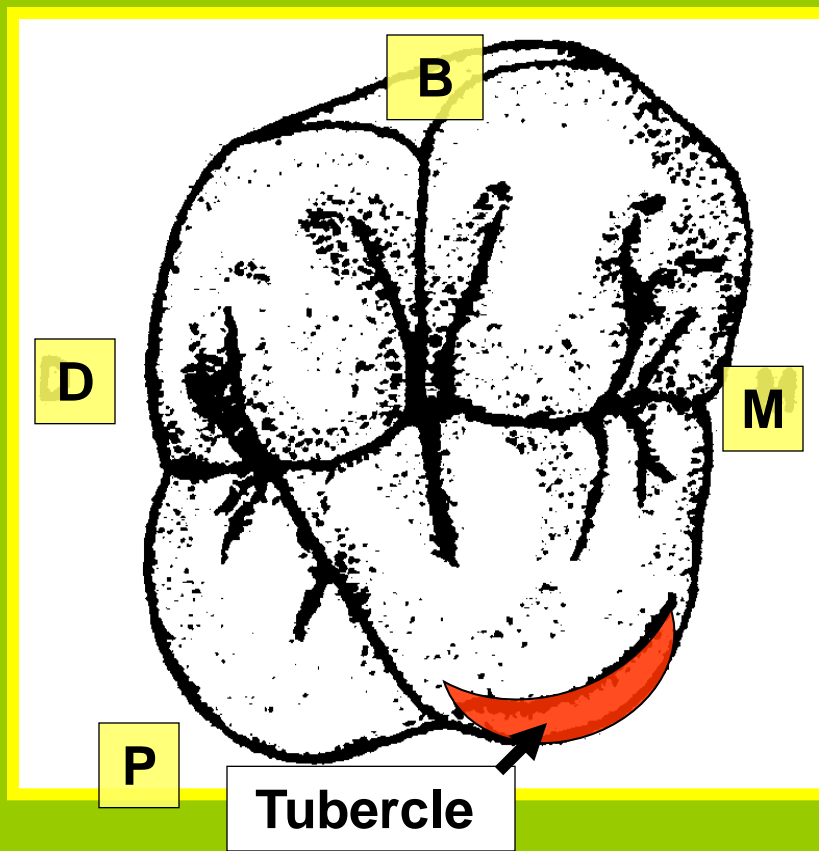
3.Cusps:

They are **pyramidal projections** on the incisal portion of the canine and on the occlusal surfaces of the premolars and molars teeth.



(II) Tubercle.

- It is a **small elevation**. It is **produced by** excessive formation of enamel.
- Tubercle is **noticed at** the palatal surface of E & 6 and sometimes at the lingual surface of incisors over the cingulum.
- **Tubercle differs from cusp** as it is formed of enamel only while cusp is formed of pulp horn covered by dentin and enamel.



(III) Ridge.

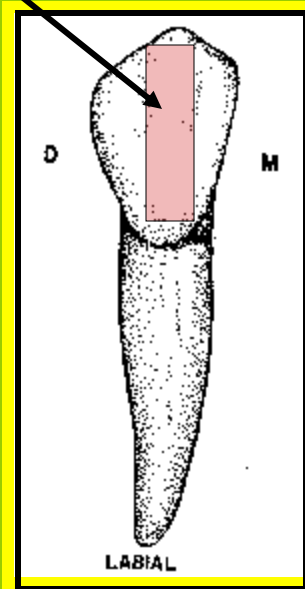
It is a *linear elevation* on the different surfaces of the crown.

A- Ridges on the facial surface (Labial and Buccal):

Labial Ridge:

Found on the labial surfaces of *canines*.

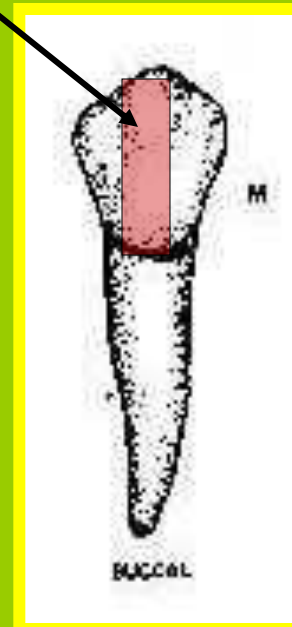
It is the result of greater development of middle labial lobe.



Buccal Ridge:

Usually found on the buccal surfaces of the *premolars*.

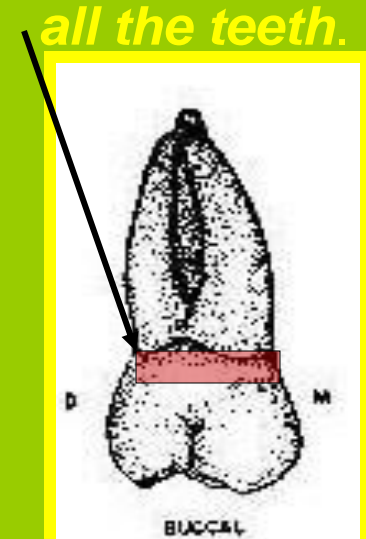
It is the result of greater development of middle buccal lobe.



Cervical Ridge:

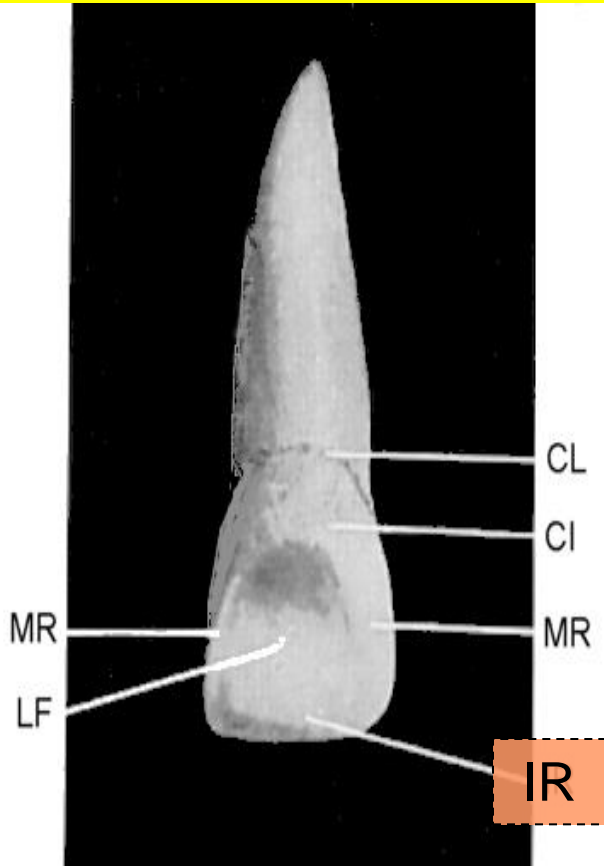
It is found on the cervical one third of the facial surfaces of *all the teeth*.

Well developed in the (D) followed by (E).



B- Ridges on the lingual surface:

1. Incisal Ridge:

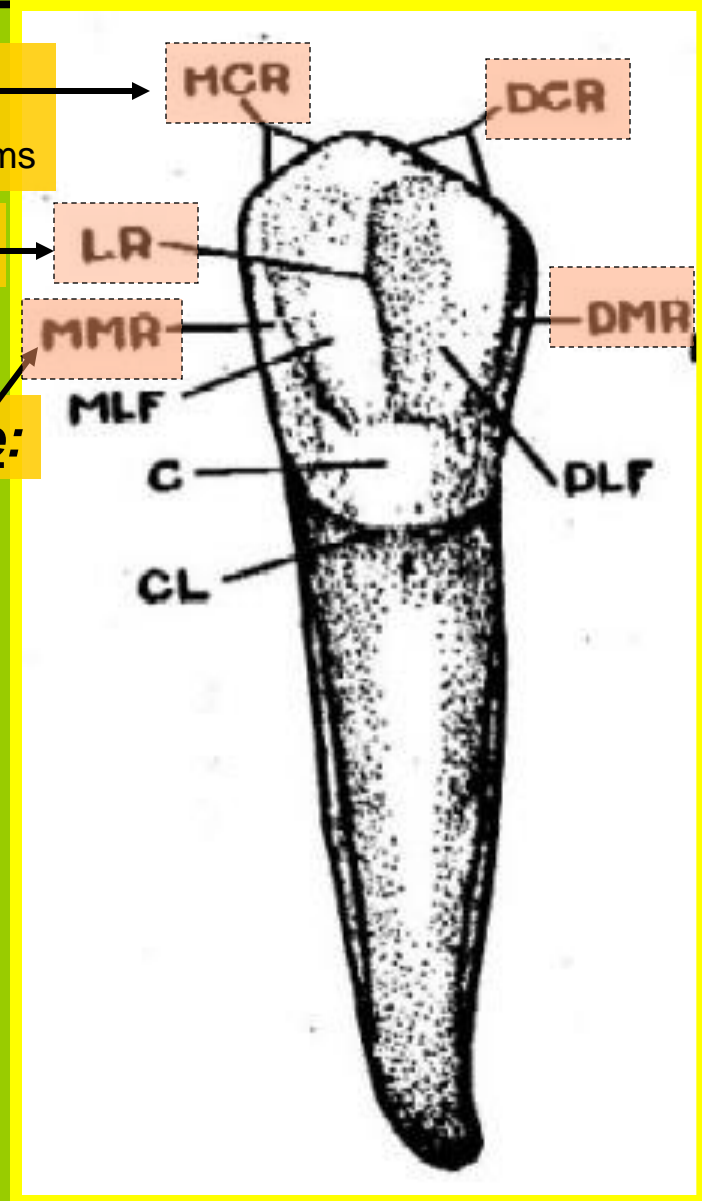


2. Cusp Ridge:

Cusp Slopes Or Cusp Arms

3. Lingual Ridge:

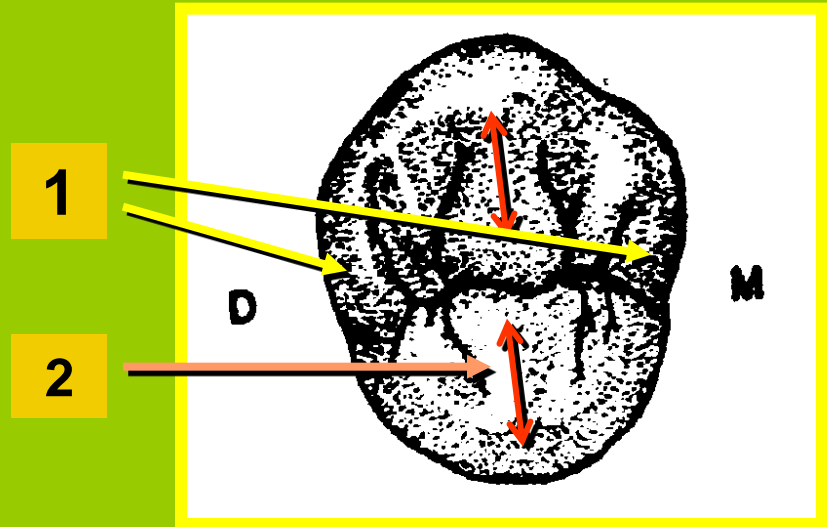
4. Marginal Ridge:



NOTE: Usually distal cusp slope is longer than mesial cusp slope in all teeth except C and 4 where the mesial cusp slope is longer than the distal

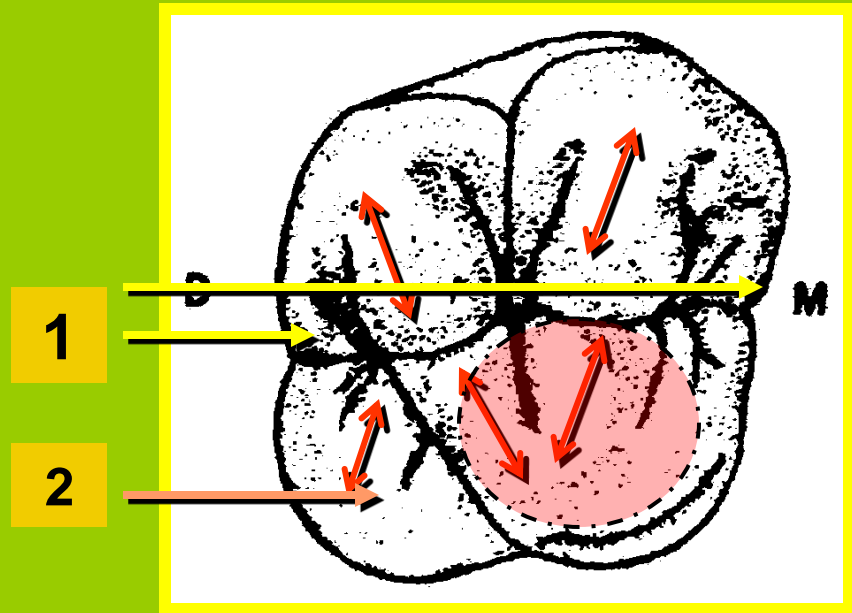
C- Ridges on the occlusal surface of posterior teeth:


1. Marginal Ridges (mesial and distal)



2. Triangular Ridges: (descend from cusp tip to the center of the occlusal surface)

All posterior tooth cusps have a triangular ridge, except the mesiolingual cusp on maxillary molars which has two triangular ridges





Cusp Ridges

Triangular R.

DBC

MBC

Cusp Tip

D

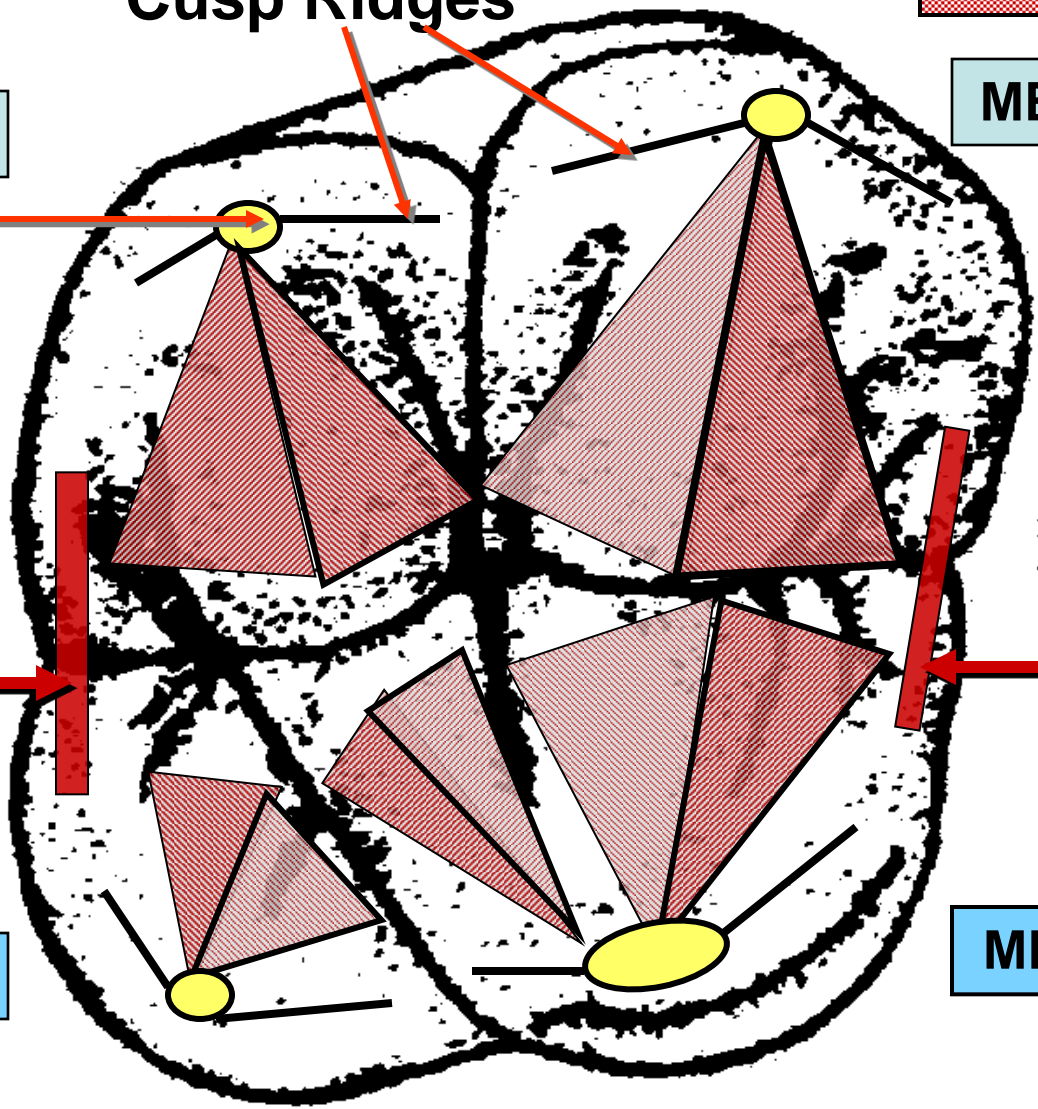
M

D M R

M M R

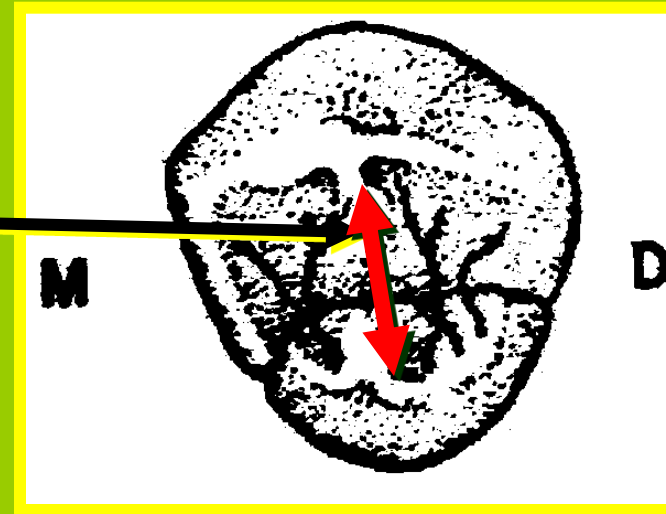
DLC

MLC



3. Transverse Ridge

(Made up of a combination of 2 triangular ridges of 2 opposing cusps)

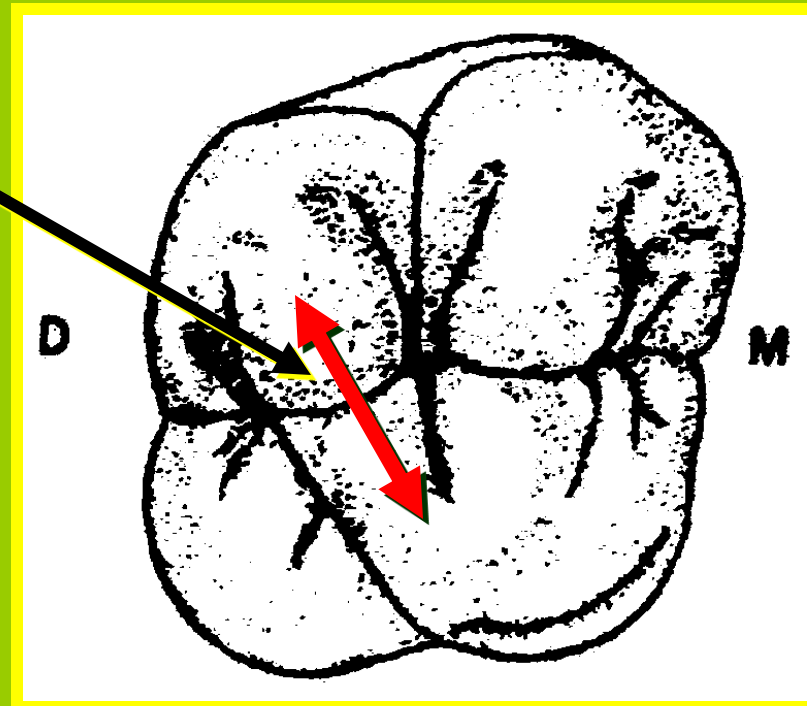


4. Oblique Ridge:

(E67 may be D, 8)

Combination of 2 triangular ridges of 2 nonopposing cusps

Remember that all teeth either anterior or posterior have cervical ridge and two marginal ridges (mesial and distal one).



ANATOMICAL LANDMARKS OF THE CROWN

CROWN ELEVATIONS

1. Lob

-Mamelones
-Cingulum
-Cusps

2. Tubercle

3. Ridges

Facial surf.

Ling. surf.

Occl. surf.

-Labial R.

-Buccal R.

-Cervical R.

-Incisal R.

-Cusp R.

-Lingual R.

-Marginal R.

(incisors & canines)

-Marginal R.

-Triangular R.

-Transverse R.

-Oblique R.

CROWN DEPRESSIONS

1. Development. Grooves

2. Supplement. Grooves

3. Fissure

4. Fossa

-Lingual
-Mesial triang.
-Distal triang.
-Central

5. Pits

6. Sulcus

B- Crown Depression:

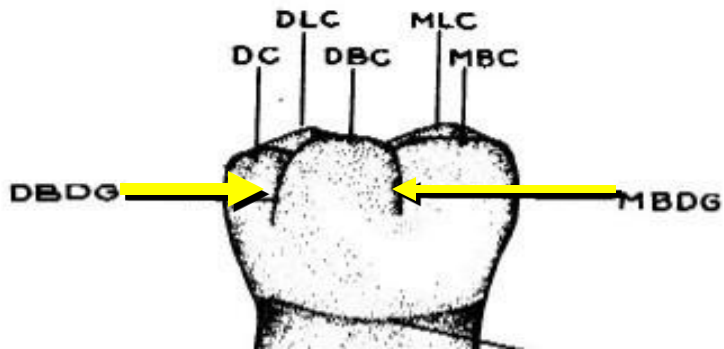
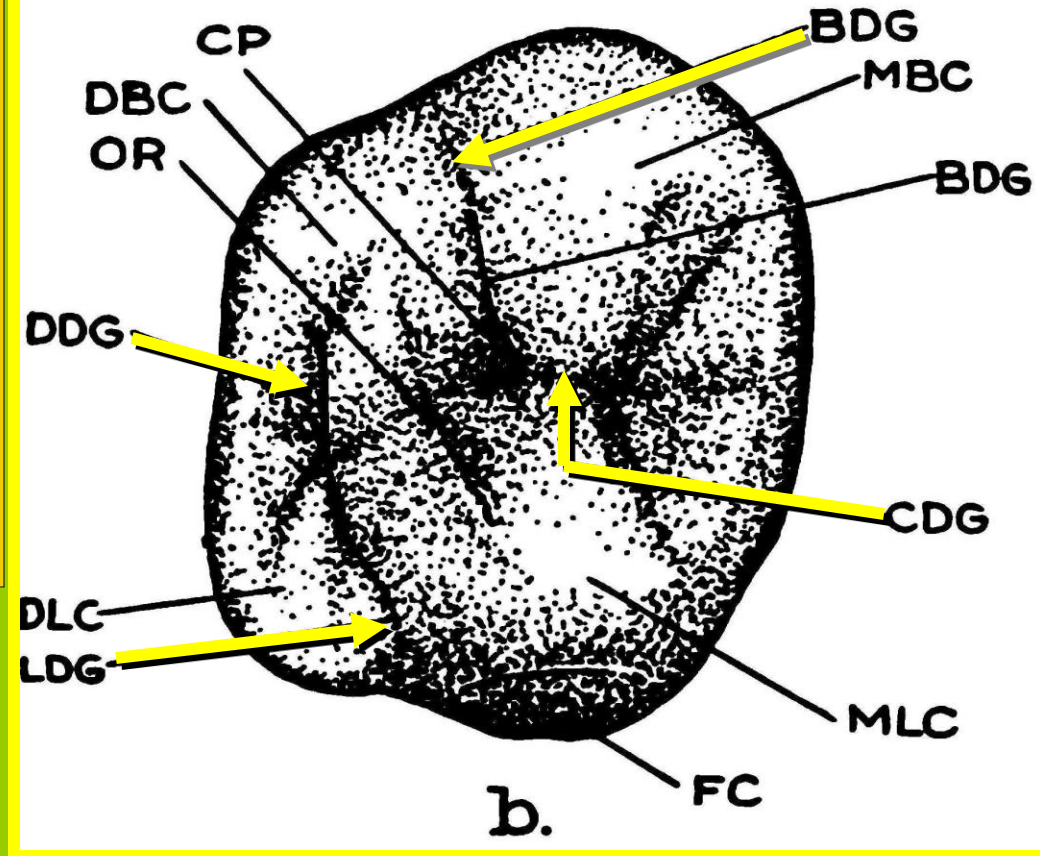
I- LINER DEPRESSIONS

1- DEVELOPMENTAL GROOVE:

It is narrow, shallow and sharply defined linear depression, short or long, denoting union of primary lobes.

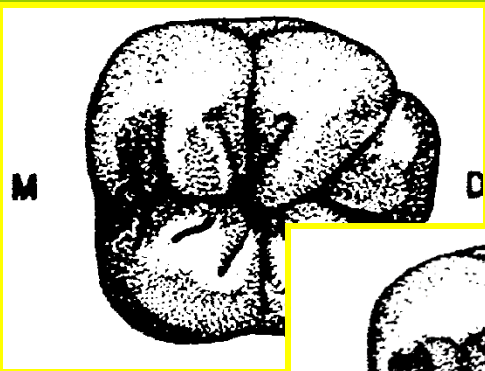
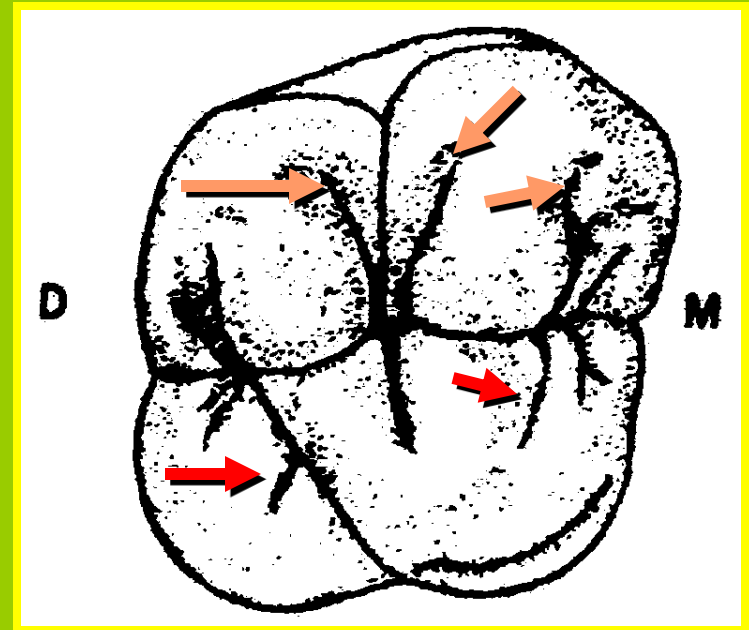
Are named according to their location.

Found in occlusal surfaces and may extend to B. and L. surfaces of posterior teeth.

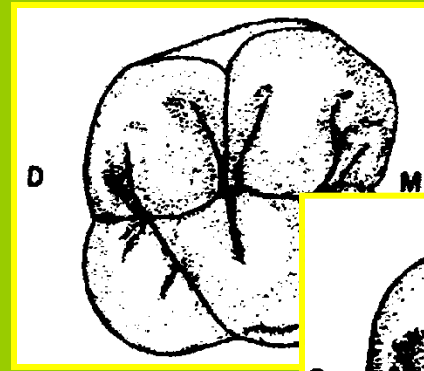


2- SUPPLEMENTAL GROOVES:


They are **small**, irregularly placed auxiliary grooves. **Branches from** developmental grooves. **Found** usually on occlusal surfaces. **They do not denote** union of primary lobes. The **third molars** followed by **second permanent molars** are characterized by high number of supplemental grooves.




6



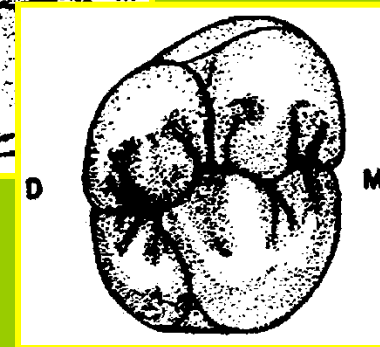
6




7



8



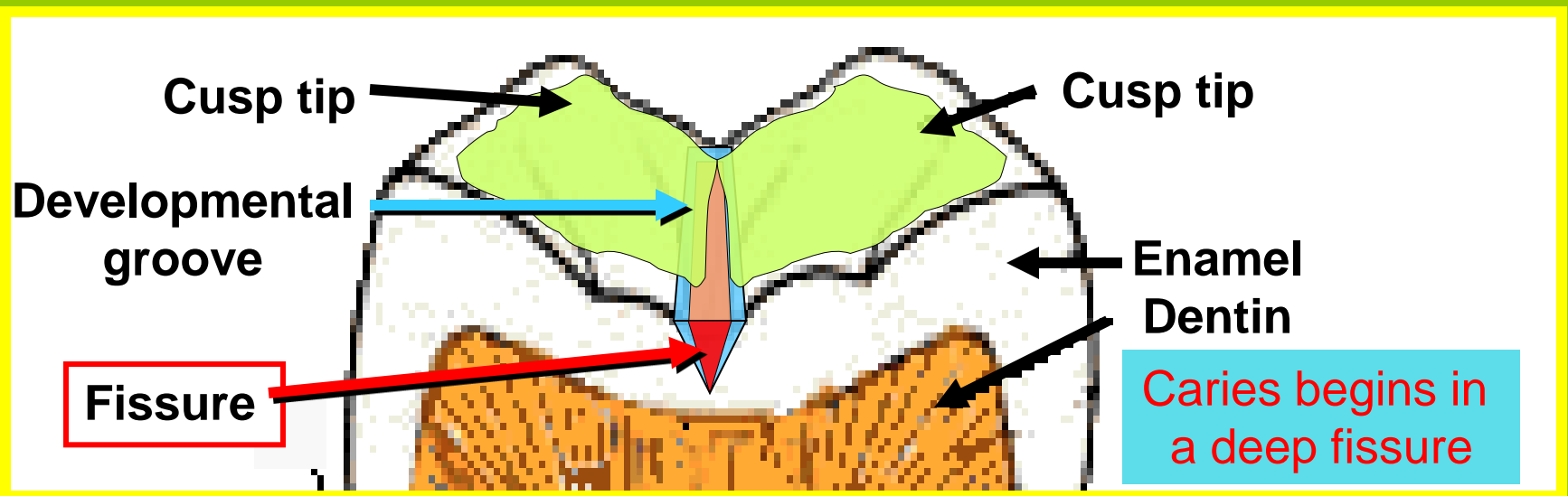
7



8

3- FISSURE:

It is **found** in the bottom of developmental groove.
Results from incomplete union of the primary lobes.
It is a **fault** in enamel.



SULCUS:

It is a broad **depression or valley** on the occlusal surfaces of posterior teeth.
Its inclines meet in a developmental groove and extend to the cusp tips.

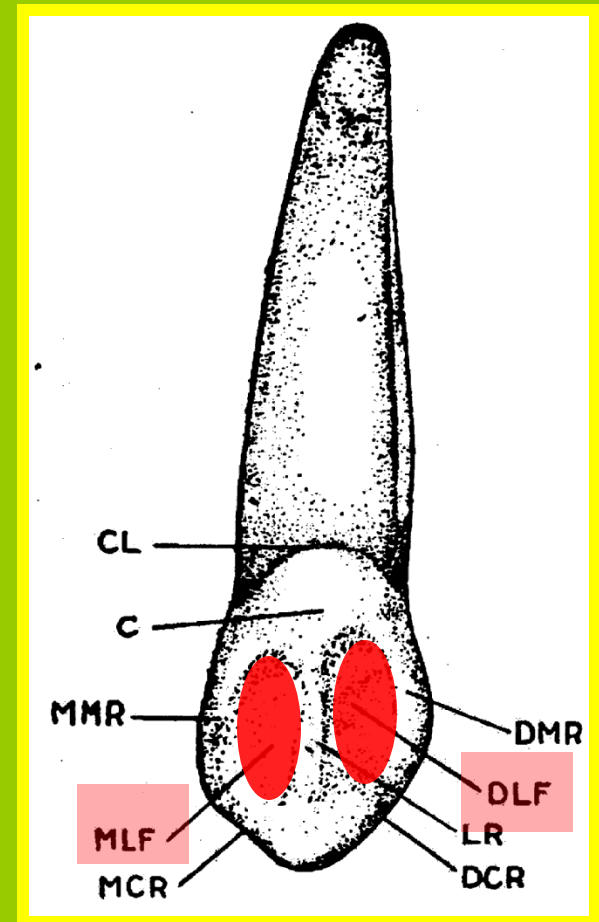
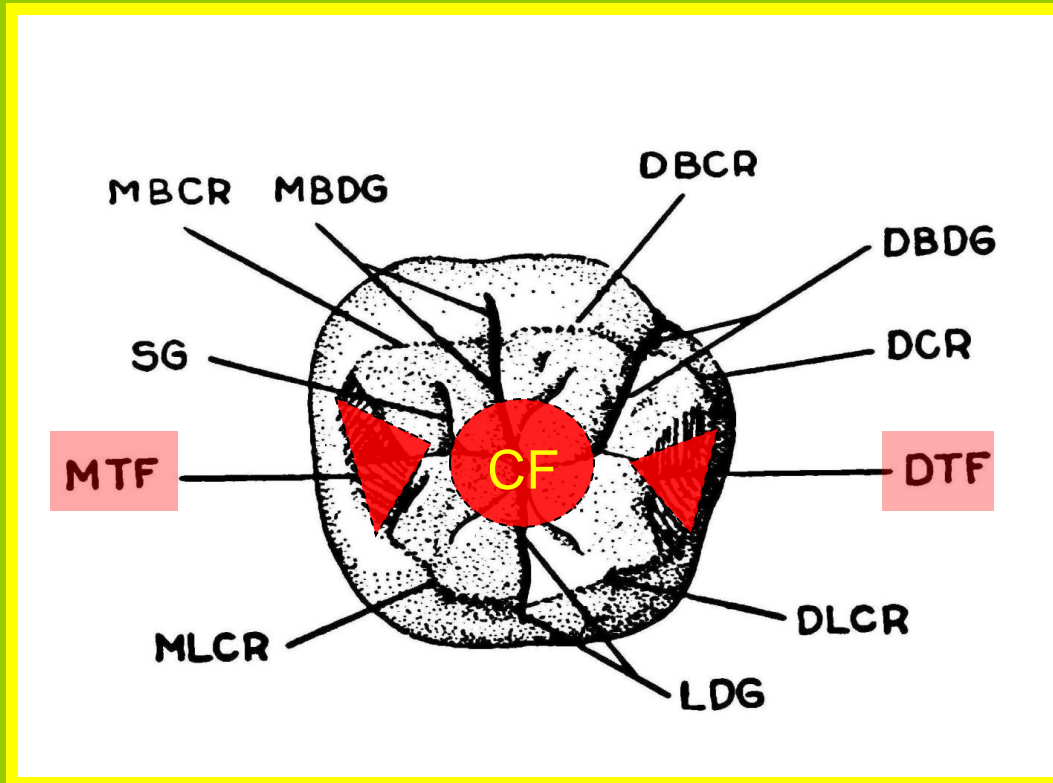
II- CIRCUMSCRIBED DEPRESSIONS

1- FOSSA:

It is a **small** depression or concavity.

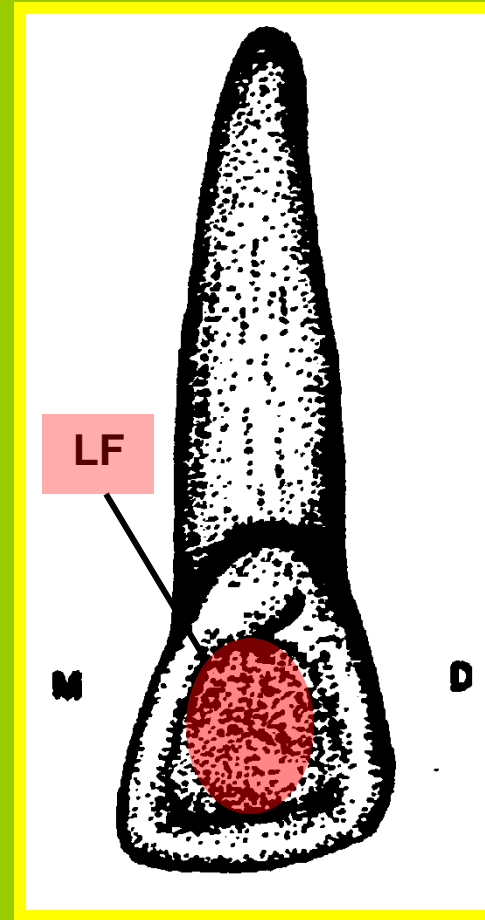
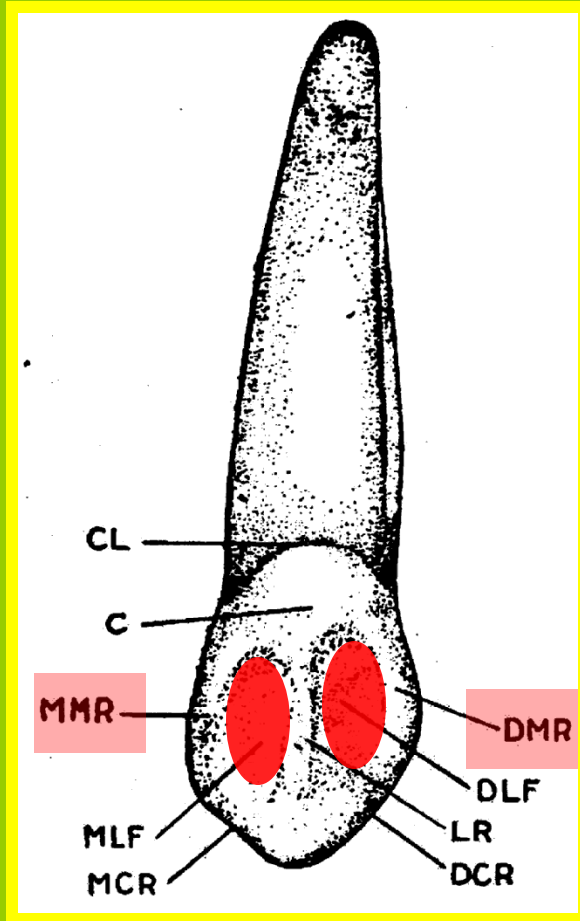
Found in both anterior and posterior teeth.

Its name is derived from its place:

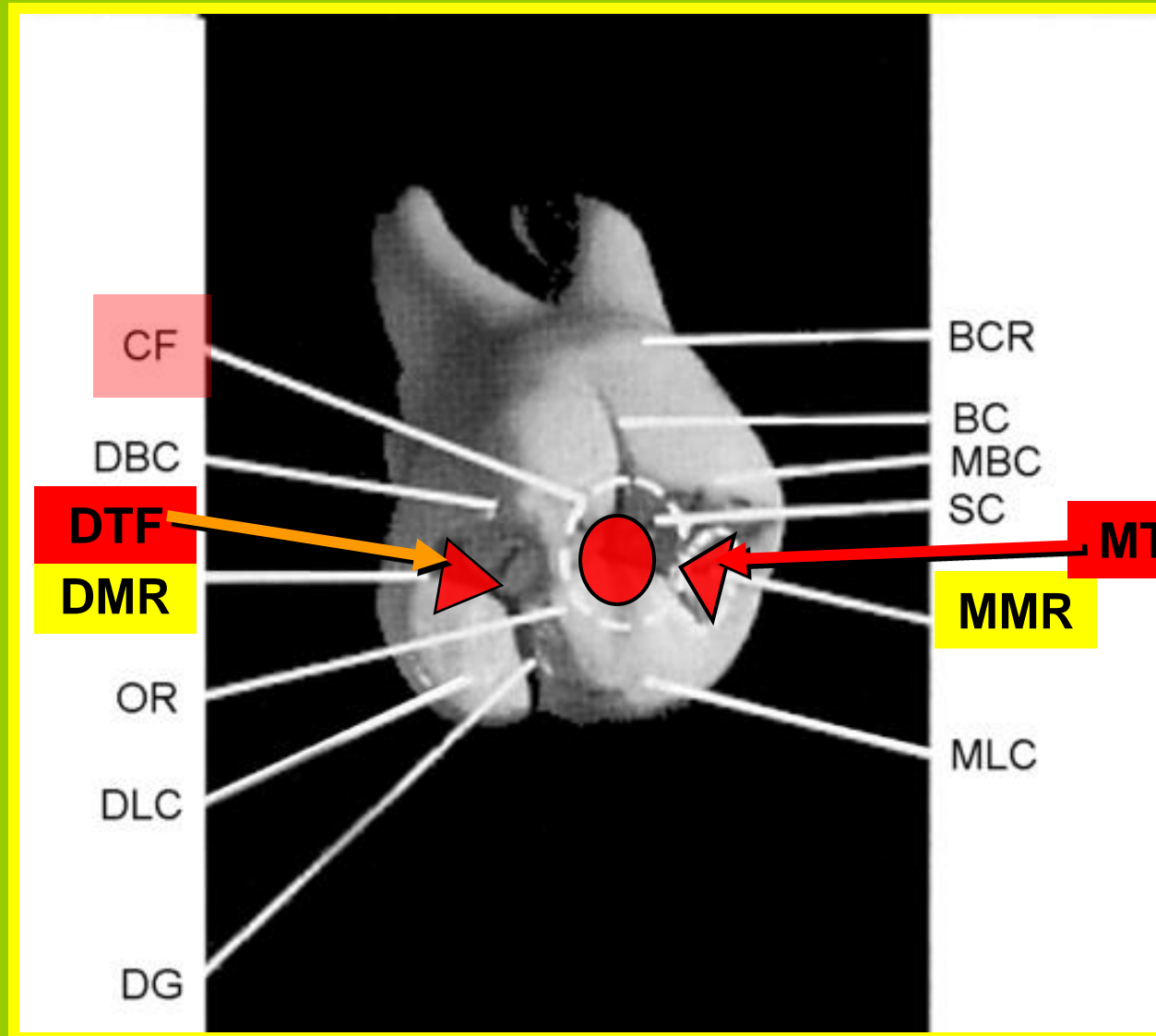


a- LINGUAL FOSSA:

Found on the lingual surfaces of anterior teeth.



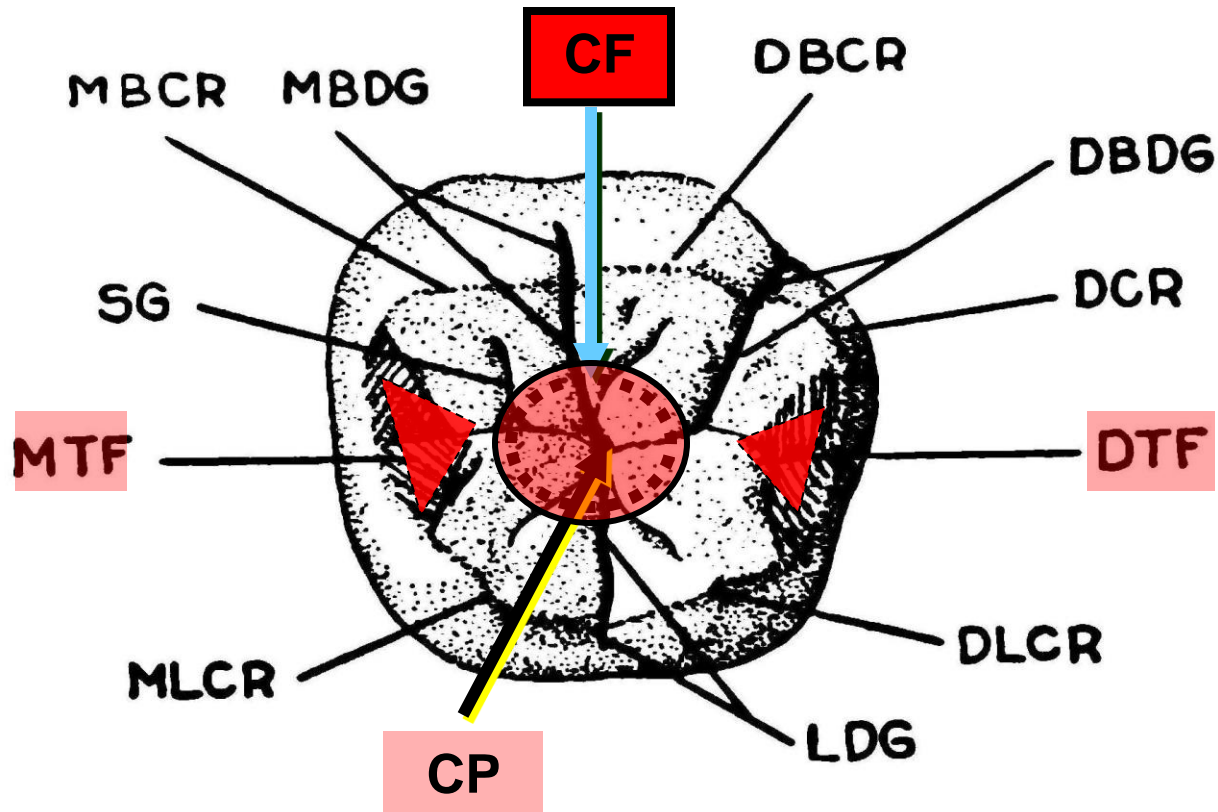
b- MESIAL AND DISTAL TRIANGULAR FOSSA:
Found on the occlusal surfaces of posterior teeth mesial and distal to the marginal ridges.



c- CENTRAL FOSSA:

Found on occlusal surfaces of molars.

They are formed by the converging of ridges terminating at a central point where there is the junction of grooves.

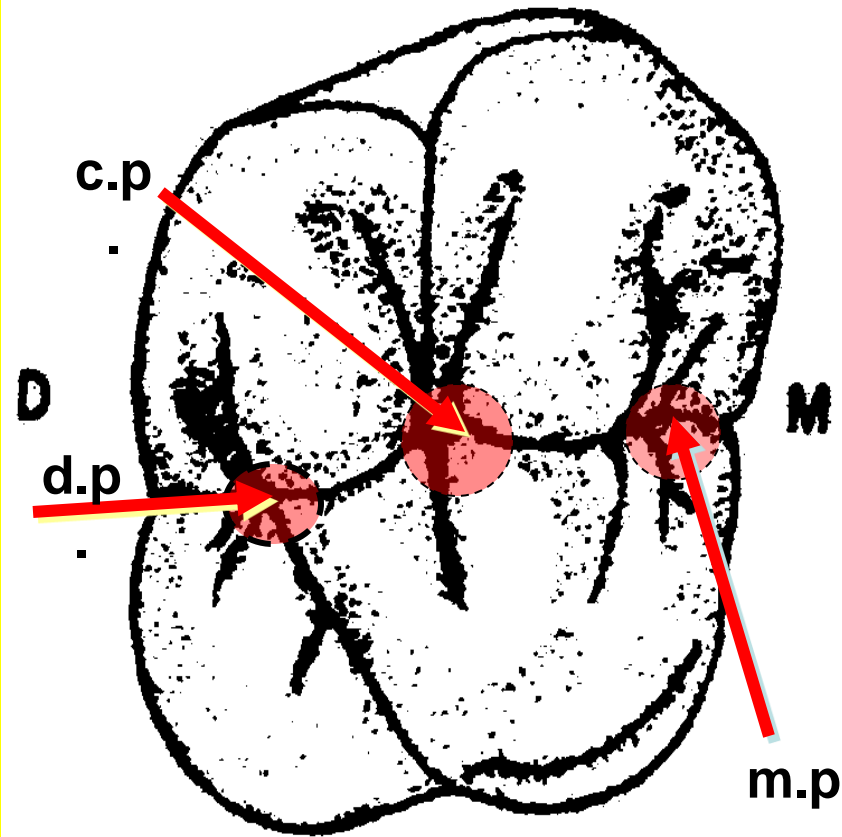


2- PITS:

a- **TRUE PITS:**

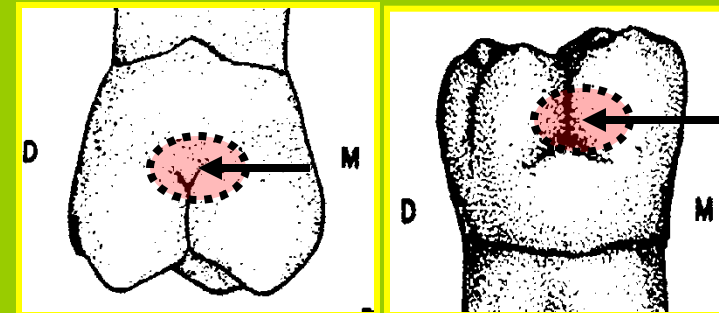
These are small **pinpoint depression** present at the junction / or at the ends of the developmental grooves.

They may be **found at the bottom** of the central fossa (**central pit**) or at the bottom of the mesial and distal triangular fossae (**mesial and distal pits**).



b- **FAULTY PIT**

Usually develops as a result of **incomplete formation of enamel**. It is **located at** the end of the buccal developmental grooves of the lower molars or palatal developmental grooves of the upper molars.


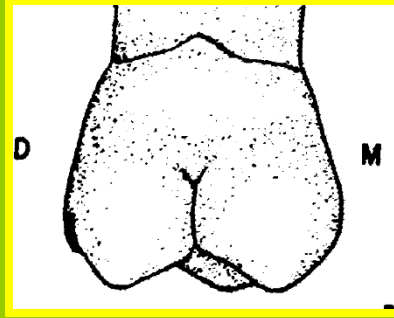
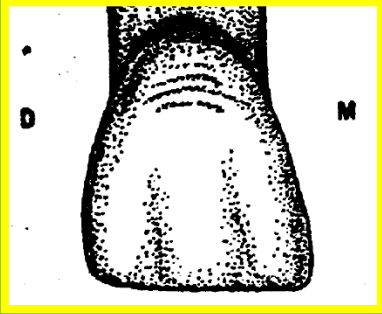


p.p.

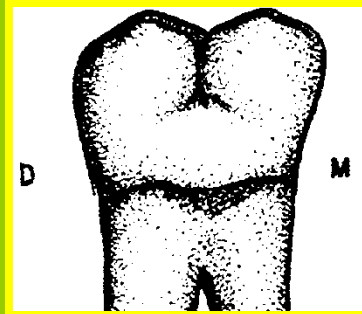
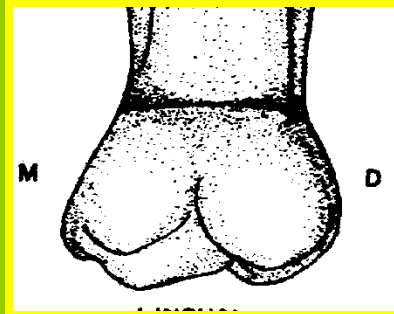
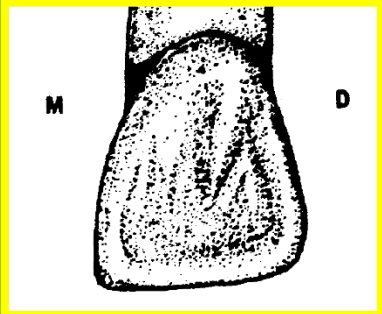
b.p.

OTHER TERMS

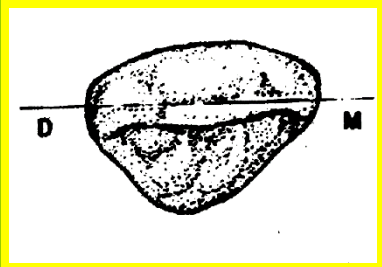
SELF CLEANSING SURFACES:




Facial



Lingual



Incisal

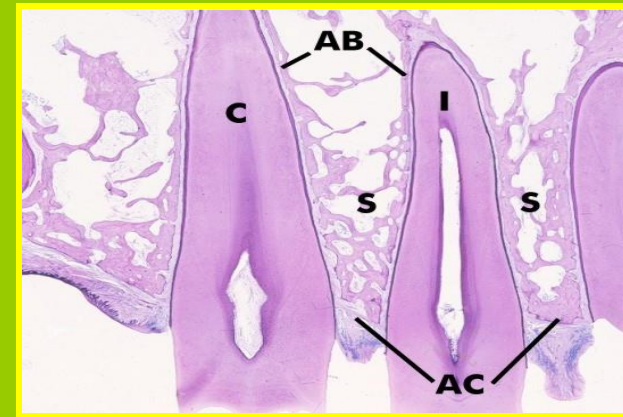
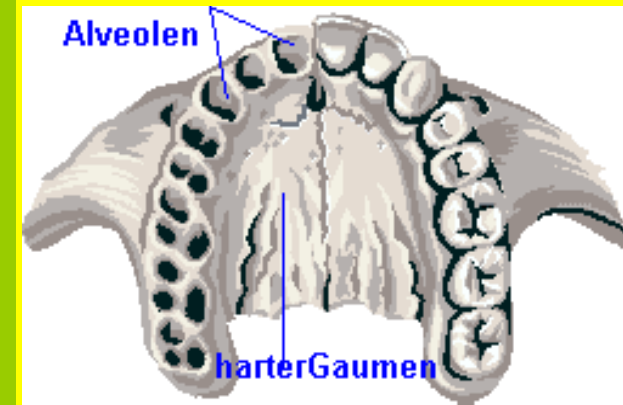
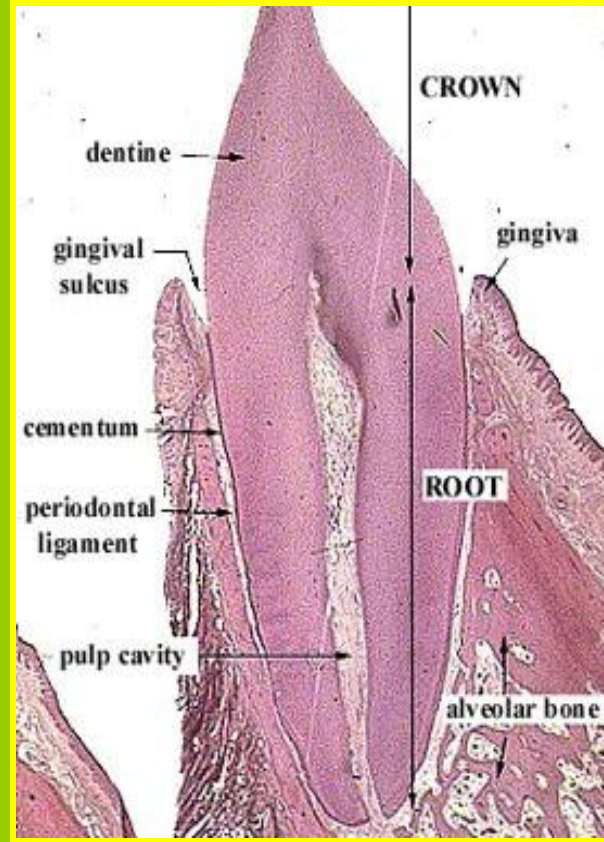
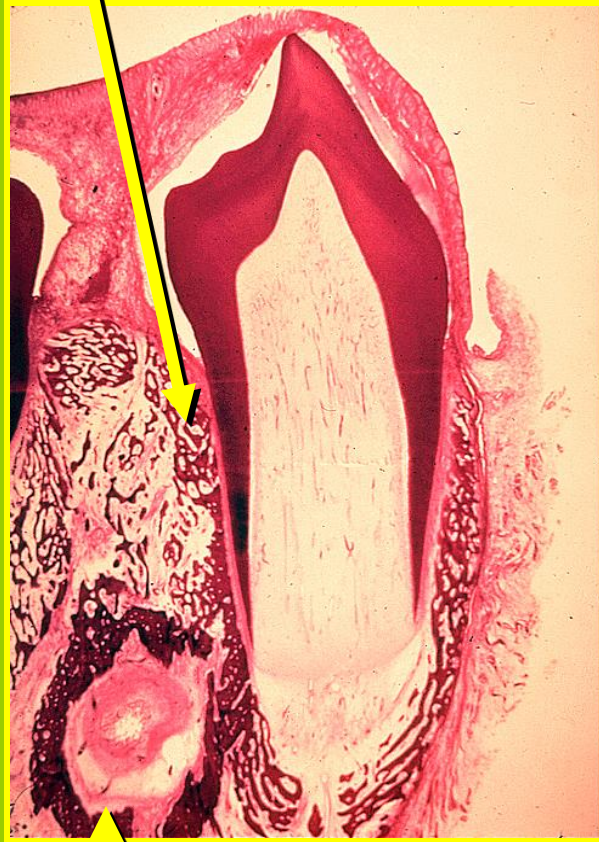


Occlusal

Those surfaces of the teeth that are cleaned by the normal functional action of the tongue, lips, cheeks and lubricated by mouth fluids.

SOCKET:

It is the ***bony space*** in the alveolar bone containing the roots of erupted tooth.

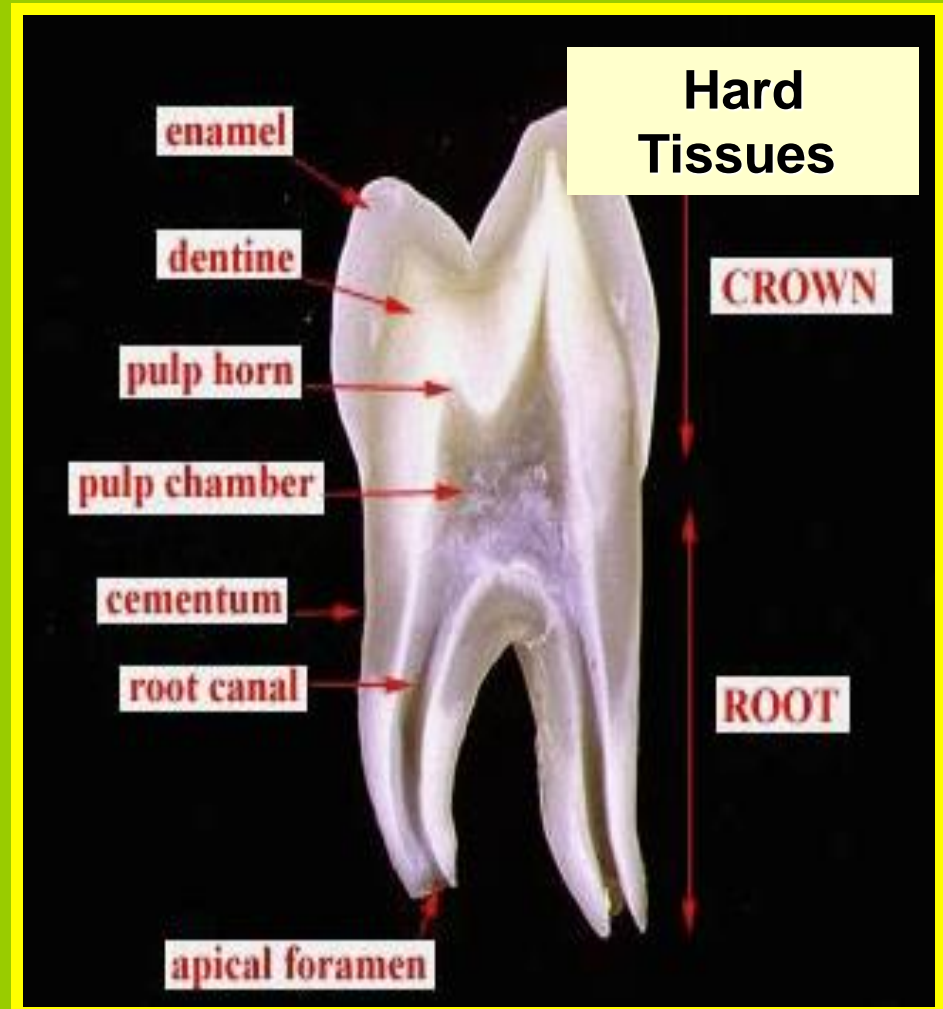
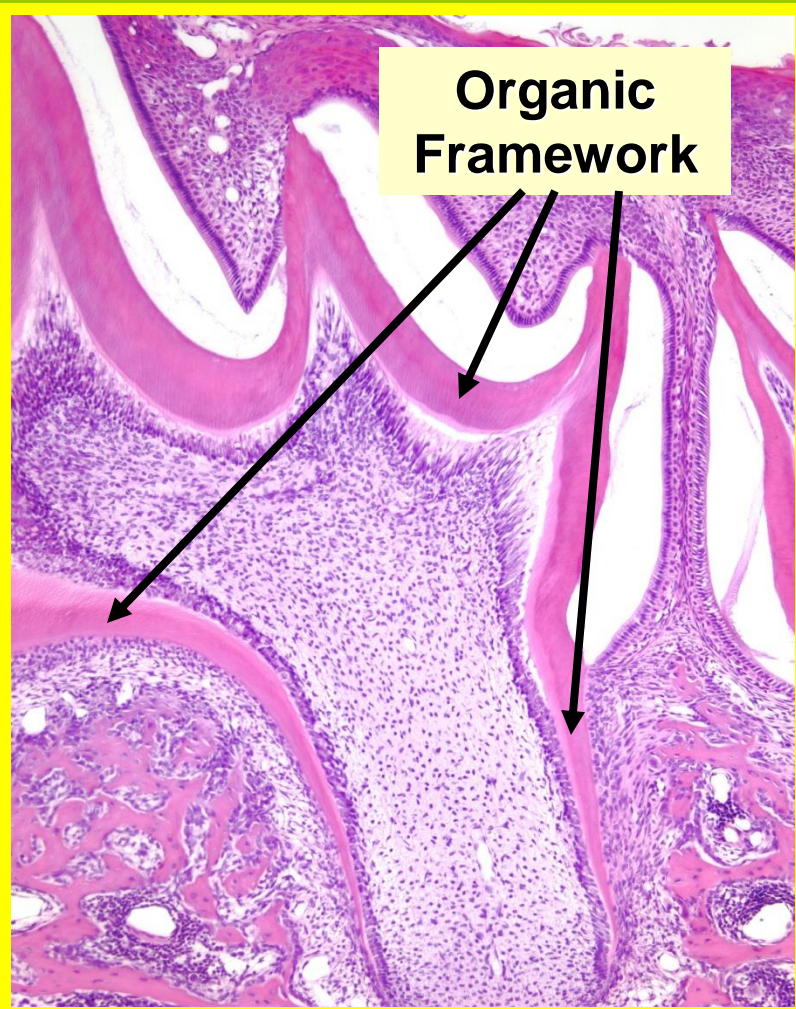


CRYPT:

It is the ***bony space*** in the alveolar bone containing the developing unerupted tooth.

CALCIFICATION:

The **organic framework of a tooth becomes hard** by deposition of **calcium** and **phosphorous salts** brought in by small blood vessels.





ZNALEZIONE NA
WWW.JOEMONSTER.ORG

THANK YOU



ANY QUESTION ?

